








# EVALUATION OF CERVICAL LORDOSIS IN PATIENTS WITH ADOLESCENT IDIOPATHIC SCOLIOSIS

*AVALIAÇÃO DA LORDOSE CERVICAL NOS PACIENTES COM ESCOLIOSE IDIOPÁTICA DO ADOLESCENTE*

*EVALUACIÓN DE LORDOSIS CERVICAL EN PACIENTES CON ESCOLIOSIS IDIOPÁTICA DEL ADOLESCENTE*

LUIS ANTONIO MEDEIROS MOLITERNO<sup>1</sup> , MATHEUS PIPPA DEFINO<sup>2</sup> , LUIZ FELIPE MOKDECI MARTINS DE OLIVEIRA<sup>1</sup> , VINICIUS TAPIE GUERRA AND SILVA<sup>1</sup> ,  
GUSTAVO BORGES LAURINDO DE AZEVEDO<sup>1</sup> , ANTONIO EULALIO PEDROSA ARAUJO JUNIOR<sup>1</sup> , JAMILA ALESSANDRA PERINI<sup>3</sup> 

1. Instituto Nacional de Traumatologia e Ortopedia (INTO), Spine Surgery Center, Rio de Janeiro, RJ, Brazil.

2. Faculdade de Medicina de Ribeirão Preto (USP), Department of Orthopedics and Anesthesiology, Column Group, Ribeirão Preto, SP, Brazil.

3. Universidade do Estado do Rio de Janeiro (UERJ), School of Biological and Health Sciences (FCBS), Pharmaceutical Sciences Research Laboratory (LAPESF), Rio de Janeiro, RJ, Brazil.

## ABSTRACT

**Introduction:** In healthy individuals and in patients with adolescent idiopathic scoliosis (AIS), the curvature of the cervical spine varies greatly, with approximately 36-40% of AIS patients having kyphosis of the cervical spine. **Aim:** To assess the curvature of the cervical spine in AIS patients and subgroups according to Lenke's classification (1 to 6). **Methods:** 107 patients with AIS were assessed for cervical lordosis (C2-C7) using the Cobb method, subdivided into lordosis and cervical kyphosis. The following parameters were assessed and compared between the subgroups: T5-T12 thoracic kyphosis (TK); L1-S1 lumbar lordosis (LL), pelvic incidence (PI), sagittal vertical axis (SVA), T1 pelvic angle (TPA), C2-C7 cervical lordosis, C1-C2 cervical lordosis, T1 slope (T1s), neck tilt, thoracic inlet angle (TIA) and cervical sagittal axis (CSVA). **Results:** Kyphosis of the cervical spine was observed in 48% of patients. The Lenke classification curves (1 to 6) showed no difference with regard to the curvature of the cervical spine. In the subgroup with cervical lordosis, thoracic kyphosis, and T1 slope were significantly higher. Neck tilt was significantly higher in the subgroup with kyphosis. **Conclusions:** Almost half of the patients have kyphosis of the cervical spine, and the curvature of the cervical spine in AIS patients varies widely. Thoracic kyphosis, T1 slope, and neck tilt are significantly different between the subgroups of patients with lordosis or kyphosis. **Level of Evidence III; Observational and Retrospective Study.**

**Keywords:** Lordosis; Scoliosis; Kyphosis; Adolescent.

## RESUMO

**Introdução:** Nos indivíduos saudáveis e nos pacientes com escoliose idiopática do adolescente (EIA) a curvatura da coluna cervical apresenta grande variação, sendo que aproximadamente 36-40% dos pacientes com EIA apresentam cifose da coluna cervical. **Objetivo:** Avaliar a curvatura da coluna cervical nos pacientes com EIA e nos subgrupos, de acordo com a classificação de Lenke (1 a 6). **Métodos:** Foram avaliados 107 pacientes com EIA quanto a lordose cervical (C2-C7), pelo método de Cobb, subdivididos em dois grupos: lordose e cifose cervical. Foram avaliados e comparados entre os subgrupos os seguintes parâmetros: cifose torácica T5-T12 (TK); lordose lombar L1-S1 (LL), incidência pélvica (PI), eixo sagital vertical (SVA), ângulo T1 pélvico (TPA), lordose cervical C2-C7, lordose cervical C1-C2, inclinação T1 (T1s), inclinação cervical (neck tilt), ângulo entrada torácica (TIA) e eixo cervical sagital (CSVA). **Resultados:** A cifose da coluna cervical foi observada em 48% dos pacientes. As curvas de classificação de Lenke (1 a 6) não apresentaram diferença com relação à curvatura da coluna cervical. No subgrupo com lordose cervical a cifose torácica e a inclinação de T1 foram significativamente maiores. A inclinação cervical foi significativamente maior no subgrupo com cifose. **Conclusões:** Quase a metade dos pacientes apresenta cifose da coluna cervical, sendo amplamente variável a curvatura da coluna cervical nos pacientes com EIA. A cifose torácica, a inclinação de T1 e a inclinação cervical são significativamente diferentes entre os subgrupos de pacientes com lordose ou cifose. **Nível de Evidência III; Estudo Observacional e Retrospectivo.**

**Descritores:** Lordose; Escoliose; Cifose; Adolescente.

## RESUMEN

**Introducción:** En individuos sanos y en pacientes con escoliosis idiopática del adolescente (EIA), la curvatura de la columna cervical varía enormemente, y aproximadamente el 36-40% de los pacientes con EIA presentan cifosis de la columna cervical. **Objetivo:** Evaluar la curvatura de la columna cervical en pacientes con EIA y subgrupos según la clasificación de Lenke (1 a 6). **Métodos:** Se evaluó la lordosis cervical (C2-C7) de 107 pacientes con EIA mediante el método de Cobb, subdivididos en dos grupos: lordosis y cifosis cervical. Se evaluaron y compararon los siguientes parámetros entre los subgrupos: Cifosis torácica (TK) T5-T12; lordosis lumbar (LL) L1-S1, incidencia pélvica (PI), eje vertical sagital (SVA), ángulo pélvico T1 (TPA), lordosis cervical C2-C7, lordosis cervical C1-C2, inclinación

Study conducted by the Instituto Nacional de Traumatologia e Ortopedia Jamil Haddad- INTO/MS, Av. Brasil, 500 - Caju, Rio de Janeiro - RJ, 20940-07, Brazil.

Correspondence: Luis Antonio Medeiros Moliterno, Av. Brasil, 500 - Caju, Rio de Janeiro - RJ, 20940-070, Brazil. [luismoliterno@yahoo.com.br](mailto:luismoliterno@yahoo.com.br)



T1 (T1s), inclinación del cuello, ángulo de la entrada torácica (TIA) y eje sagital cervical (CSVA). Resultados: Se observó cifosis de la columna cervical en el 48% de los pacientes. Las curvas de clasificación de Lenke (1 a 6) no mostraron diferencias con respecto a la curvatura de la columna cervical. En el subgrupo con lordosis cervical, la cifosis torácica y la inclinación T1 eran significativamente mayores. La inclinación cervical fue significativamente mayor en el subgrupo con cifosis. Conclusiones: Casi la mitad de los pacientes presentan cifosis de la columna cervical, y la curvatura de la columna cervical en los pacientes con EIA varía ampliamente. La cifosis torácica, la inclinación T1 y la inclinación cervical son significativamente diferentes entre los subgrupos de pacientes con lordosis o cifosis. Nivel de Evidencia: III; Estudio Observacional y Retrospectivo.

**Descriptor:** Lordosis; Escoliosis; Cifosis; Adolescente.

## INTRODUCTION

The lordotic curvature of the cervical spine appears around the tenth week of fetal life. The curvature of the cervical spine varies widely among asymptomatic individuals, and about 35% of asymptomatic individuals have kyphosis of the cervical spine.<sup>1,2</sup> The values depend on the assessment method, and four methods have already been proposed for evaluating the curvature of the cervical spine, based on lines drawn on the vertebral plates or the back surface of the vertebral bodies: Cobb C2-C7, Ishihara index, Harrison's C2-C7 rear tangent, and curve area.<sup>3</sup>

The incidence of cervical spine kyphosis in patients with adolescent idiopathic scoliosis (AIS) is higher compared to normal individuals.<sup>4</sup> Kyphosis of the cervical spine in patients with AIS has been observed in 36-40% of patients and is considered an effect of thoracic hypokyphosis on the cervical spine.<sup>5,6</sup> The average kyphosis of 11° was observed in 34% of patients with AIS and with minor thoracic kyphosis of 17°. The increase in cervical lordosis, which would represent a compensatory effect on the increase in thoracic kyphosis, has been reported in the disease by Scheuermann.<sup>8</sup>

Initially, the thoracolumbar spine was the focus of the study of sagittal alignment and balance. This concept was extended to the cervical spine and the growing number of publications highlights the interest in the topic. In this context, the objective of the study was to assess the prevalence of kyphosis or lordosis of the cervical spine in patients with AIS and to compare it in the different types of curves, according to the Lenke classification.<sup>9</sup>

## METHODS

The study was approved by the Institutional Research Ethics Committee (IREC): 39839820.2.0000.5273), with 107 patients with AIS of both genders and with indications for surgical treatment being evaluated retrospectively.

Panoramic anteroposterior (AP) radiographs and profiles in the orthostatic position were used to assess the angulation of the proximal thoracic, principal thoracic, and lumbar curves to classify the curves according to Lenke's classification (type 1 to 6) and to evaluate the parameters selected for the study: thoracic kyphosis T5-T12 (TK); lumbar lordosis L1-S1 (LL), pelvic incidence (PI), sagittal vertical axis (SVA), T1 pelvic angle (TPA), cervical lordosis C2-C7, cervical lordosis C1-C2, inclination T1 (T1s), cervical inclination (neck tilt), angle of thoracic entrance (TIA), and sagittal cervical axis (SCA).

The patients were divided into two subgroups according to the C2-C7 angulation and classified as cervical lordosis (negative angle - vertex of the lower plate angle of C2 and C7 posterior) and cervical kyphosis (positive angle - vertex of the angle of the lower plate of C2 and C7 - anterior). The parameters selected for the study were compared between patients with C2-C7 lordosis and C2-C7 kyphosis. The C2-C7 lordosis was compared between the different types of Lenke classification curves. Negative Cobb angle values indicated lordosis and positive values indicated kyphosis.

The data were analyzed using the Prism graphpad program — version 10. The Kolmogorov-Smirnov test was used to assess the normality of the sample, the Student t-test to compare parameters between subgroups with lordosis or C2-C7 kyphosis, and the ANOVA test to compare the C2-C7 angulation in the different types of Lenke classification curves. Statistical significance was set at 5% ( $p < 0.05$ ).

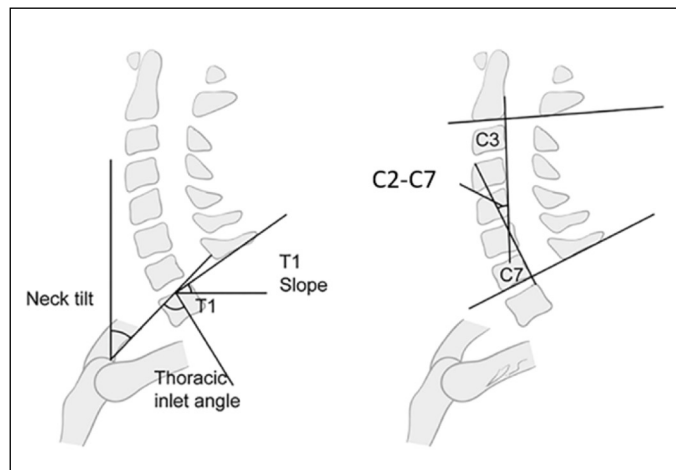
## RESULTS

A mount of 107 patients (84% female), with a mean age of 21.8 and 4.9 years, were evaluated. Forty-six patients (43.0%) had Lenke type curves 1, 7 (6.5%) Lenke 2, 23 (21.5%) Lenke 3, 5 (4.7%) Lenke 4, 14 (13.1%) Lenke 5, and 12 (11.2%) Lenke 6.

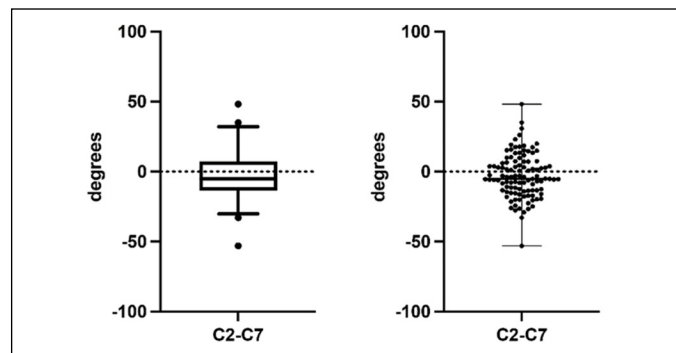
The angulation of the C2-C7 segment, evaluated using the Cobb C2-C7 angle (Figure 1), was observed in 48% of the patients and ranged from -53.10 to 48.10 degrees (-3.12 15.67), according to the distribution of the values illustrated in Figure 2.

The distribution of the C2-C7 angle values of the cervical lordosis of the 107 patients with AIS analyzed is illustrated in Figure 3. Cervical lordosis was observed in 62 patients and ranged from -2.5 to -53.1 degrees. Kyphosis was observed in 45 patients and ranged from 0.5 to 48.1 degrees.

There was no statistical difference between the values of the C2-C7 angle of cervical lordosis in the different types of curves



**Figure 1.** Schematic figure showing sagittal cervical parameters evaluated by the Cobb angle C2-C7. Neck tilt = cervical inclination. Thoracic inlet angle = thoracic entrance angle (TIA). T1 slope = T1 slope. C2-C7 = angle of the cervical lordosis.



**Figure 2.** Distribution of angle C2-C7 values in 107 patients with AIS. The graph on the left illustrates the median, the quartiles, and the maximum and minimum values. The graph on the right illustrates the spread of the values, the median, and the maximum and minimum values.

from the Lenke classification 1 to 6 (Kruskal-Wallis test —  $p < 0.05$ ). (Table 1 and Figure 4)

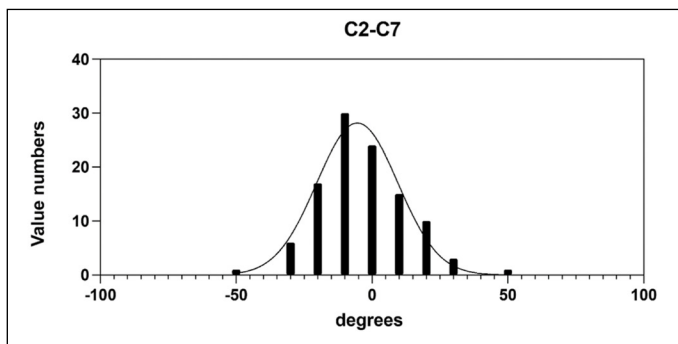
The frequency and distribution of the angular values of the C2-C7 segment in the different types of the Lenke classification (1 to 6) are represented in Figure 5. There was no statistical difference between SVA, TPA, PI, PT, LL, cervical SVA, C1-C2 angulation, and TIA between subgroups with lordosis or kyphosis.

A statistical difference was observed in thoracic kyphosis (TK), T1 inclination, and cervical inclination between subgroups with lordosis or kyphosis of the cervical segment C2-C7. (Figures 6, 7 and 8)

**DISCUSSION**

Kyphosis of the C2-C7 segment was observed in 48% of patients with AIS and no significant difference was observed between subgroups, according to the Lenke classification curves. A significant difference was observed between thoracic kyphosis, T1 inclination, and cervical inclination between the sub-groups of patients with AIS with lordosis or kyphosis.

Classically, cervical lordosis has been described as the pattern

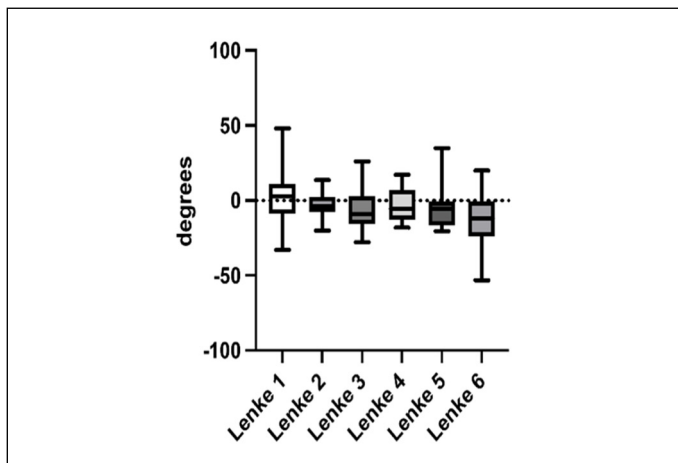


**Figure 3.** Gaussian distribution of the C2-C7 angle values of cervical lordosis in 107 patients with AIS.

**Table 1.** Cervical lordosis angle C2-C7 values in the different types of Lenke classification curves (1 to 6) of the 107 patients included in the study.

	Lenke 1 (n = 46)	Lenke 2 (n = 7)	Lenke 3 (n = 23)	Lenke 4 (n = 5)	Lenke 5 (n = 14)	Lenke 6 (n = 12)
Minimum	-33	-20.1	-27.7	-18.1	-20.5	-53.1
Maximus	48.1	13.5	26	17.3	34.9	19.9
Average	0.8804	-3.243	-5.548	-3.42	-3.743	-12.9
DP	15.86	10.44	14.78	12.93	14.7	18.48

SD = standard deviation.



**Figure 4.** The C2-C7 angle values were distributed in the different types of Lenke classification curves (1 to 6) of the 107 patients with AIS. There was no statistical difference regarding the angle C2-C7 between the different types of curves (Kruskal-Wallis-  $p < 0.05$ ).

of curvature of the cervical spine. However, cervical spine kyphosis has been described in about 30% of asymptomatic individuals.<sup>10-12</sup> The angulation of the cervical spine varies widely and the occipital-C2 segment has the largest share in the curvature of the cervical spine. In asymptomatic individuals, the occipital angle -C2 ranges from -12.3 to -32.5 and from -4.1 to -16.3, and in the C2-C7 segment according to age and gender.<sup>5</sup> In asymptomatic individuals, C2-C7 lordosis ranges from -16 gaus +-16 in men and -15 +-10 gaus in women.<sup>2,13</sup> The analysis of the results is hampered by the lack of consensus about the normal alignment of the cervical spine, which has shown changes in concept. The angle of the cervical curvature  $> 0$  and C2-C7 SVA  $> 4$ mm was the limit initially considered for the definition of cervical deformity.<sup>13</sup> Subsequently, these values were changed to C2-C7 kyphosis  $> 10$  cm and C2-7 SVA  $> 4$  cm, based on the analysis combined with quality-of-life questionnaires.<sup>14</sup> The use of morphological criteria for the assessment of cervical lordosis presents results different from isolated angular values.<sup>4</sup>

Although there was no difference in cervical lordosis between the different types of Lenke curves in the 107 patients analyzed, it is important to emphasize that all had surgical treatment indications and high-grade curves. Cervical lordosis has been reported to decrease with increasing Cobb angle in patients with  $\geq 45^\circ$  curves. This correlation was not observed in the group of patients with curves  $> 45^\circ$ .

The frequency of patients with cervical spine kyphosis observed in this study is in line with what has already been described.<sup>15</sup> The morphology of the cervical spine varies widely among patients with AIS, and a considerable percentage have cervical spine kyphosis. The ideal reconstruction of the cervical spine is a point of discussion, and there are reports of better results in patients with maintenance of lordosis.<sup>16</sup>

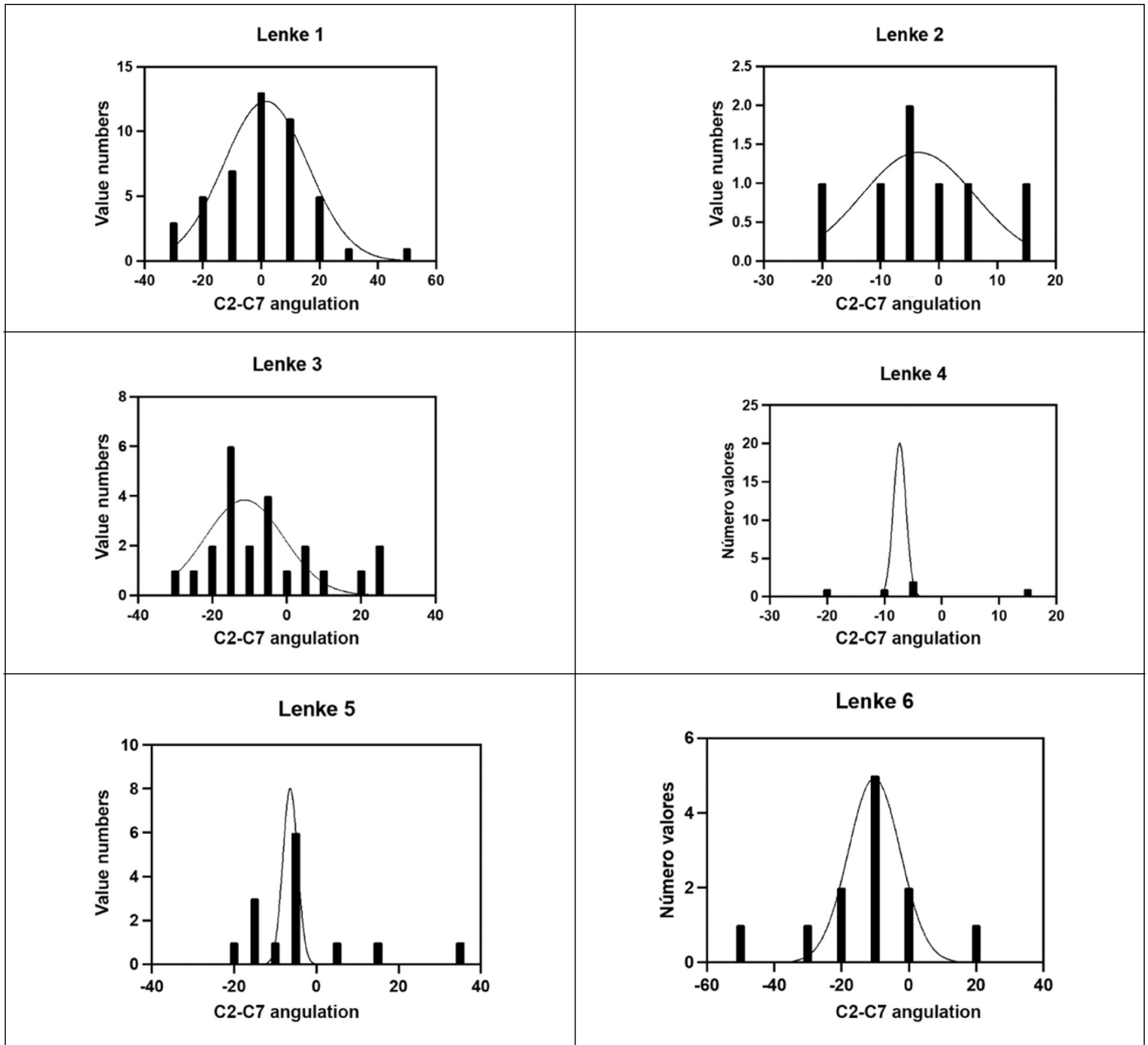
The difference in thoracic kyphosis between subgroups with lordosis or kyphosis of the cervical spine is in line with literature reports, and it has already been observed that the reduction of thoracic kyphosis affects the curvature of the cervical spine.<sup>17</sup> Restoration of thoracic kyphosis and alteration of T1 inclination have been associated with improved cervical curvature.<sup>18-21</sup> The significant difference observed in the present study in relation to the T1 inclination between subgroups with lordosis or kyphosis is in line with previous reports, which suggest this parameter's importance in assessing the cervicothoracic junction.<sup>22</sup>

Patients with cervical spine kyphosis in this study had lower thoracic kyphosis and T1 inclination, in line with existing literature.<sup>23</sup> Therefore, the T1 inclination has a direct effect on cervical curvature.<sup>23</sup>

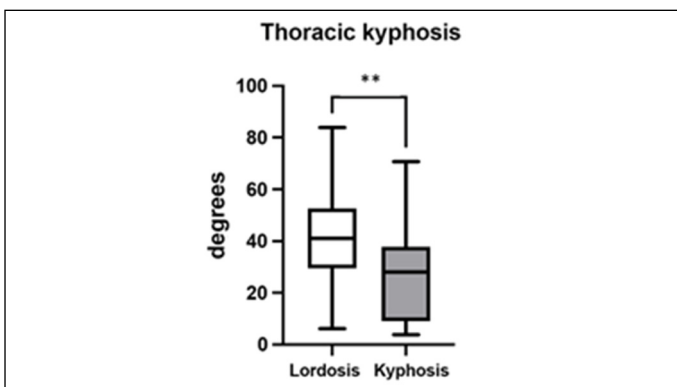
The T1 inclination and neck tilt sum correspond to the thoracic inlet angle. This concept was introduced considering that the morphology of the upper opening of the thoracic spine could influence the alignment of the skull and cervical spine. In the present study, the cervical inclination was greater in the subgroup of patients with kyphosis, showing the compensation that occurs to maintain spinal alignment in patients with AIS. This parameter has an inverse relationship with the slope of T1.<sup>5</sup>

Although the total number of patients analyzed is significant, the study has some limitations, such as the reduced number in some subgroups, according to the Lenke classification, hampering comparisons between the different types of curvature. According to the literature, Lenke 1-type curves predominated in the present study.<sup>9</sup> Furthermore, because it is a retrospective study in which radiographic images were taken during routine care, it is possible that there may be a difference in radiographic parameters since the positioning of the patients to perform the radiographic examination may alter the result of the measurements. However, all patients were treated at the same location, a tertiary hospital in the Brazilian public health system, a reference center for diagnosing and treating highly complex orthopedic diseases. This also explains the fact that all 107 patients studied had indications for surgical treatment and high-grade curves, which should be considered in comparison with other reports that used lower-grade curves.

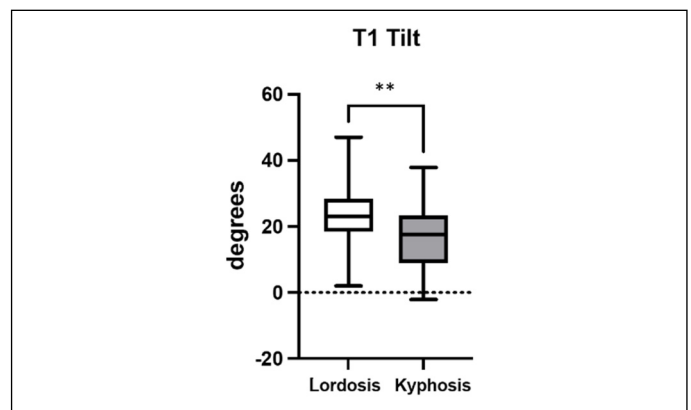
Finally, it should be noted that cervical spine kyphosis is



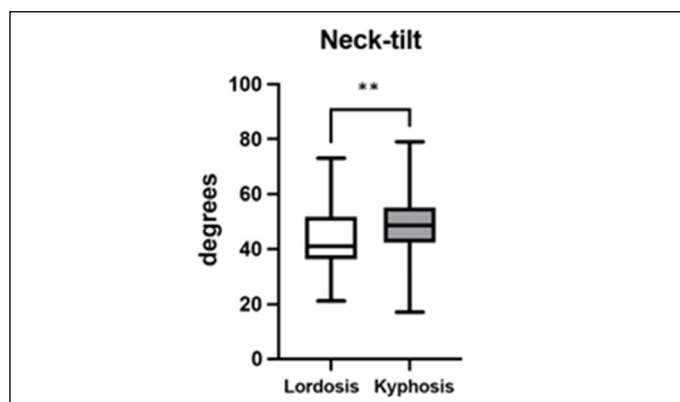
**Figure 5.** Distribution of the angular values of cervical lordosis measured between C2-C7 in the different types of the Lenke classification (1 to 6) considering the 107 patients analyzed.



**Figure 6.** Angular values (minimum, maximum, and average) of thoracic kyphosis (T5-T12) in subgroups with lordosis and C2-C7 kyphosis. The asterisks indicate the statistical difference between the two groups considering the 107 patients with AIS (Mann-Whitney test —  $p < 0.05$ ).



**Figure 7.** Angular values (minimum, maximum, and average) of the T1 slope in lordosis and C2-C7 kyphosis subgroups. The asterisks indicate the statistical difference between the two groups (Student t-test—  $p < 0.05$ ).



**Figure 8.** Angular values (minimum, maximum, and average) of the cervical inclination (neck tilt) in the subgroups with lordosis and C2-C7 kyphosis, considering the 107 patients included. The asterisks indicate the statistical difference between the two groups (Mann-Whitney test —  $p < 0.05$ ).

present in asymptomatic individuals and in patients with AIS. In patients with AIS, the curvature of the cervical spine varies significantly between lordosis and kyphosis. The alignment of the cervical spine is interrelated with other sagittal parameters of the vertebral spine,<sup>24</sup> and global and regional alignment must be analyzed individually in patients.

## CONCLUSION

No significant difference was observed between the Lenke classification subgroups (1 to 6) considering the kyphosis of the C2-C7 segment, present in 48% of patients with AIS. A significant difference was observed between thoracic kyphosis, T1 inclination, and cervical inclination when comparing subgroups of patients with lordosis or kyphosis.

All authors declare no potential conflict of interest related to this article.

**CONTRIBUTIONS OF THE AUTHORS:** Each author contributed individually and significantly to the development of this article. LAMM: surgery, data collection, research project preparation, statistical analysis, and manuscript writing. MPD: statistical analysis, interpretation of the results, and writing of the manuscript. LFMMO: surgery and data collection. VTGS: surgery and data collection. GBLA: surgery and data collection. AEP AJ: surgery and data collection. JAP: Coordination of the research project and review of the manuscript.

## REFERENCES

- Bagnall KM, Harris PF, Jones PR. A radiographic study of the human fetal spine. The development of the secondary cervical curvature. *J Anat.* 1977;123(Pt 3):777-82.
- Gore D, Sepic S, Gardner G. Roentgenographic findings of the cervical spine in asymptomatic people. *Spine.* 1986;11(6):521-4.
- Guo GM, Li J, Diao QX, Zhu TH, Song ZX, Guo YY, et al. Cervical lordosis in asymptomatic individuals: A metaanalysis. *J Orthop. Surg. Res.* 2018;13(1):147.
- Han SM, Wen JX, Cao L, Wu HZ, Liu C, Yang C, et al. Sagittal morphology of the cervical spine in adolescent idiopathic scoliosis: a retrospective case-control study. *Quant Imaging Med Surg.* 2022;12(6):3049-60.
- Lee SH, Hyun SJ, Jain A. Cervical Sagittal Alignment: Literature Review and Future Directions. *Neurospine.* 2020;17(3):478-96.
- Hilibrand A, Tannenbaum D, Graziano G, Loder RT, Hensinger RN. The sagittal alignment of the cervical spine in adolescent idiopathic scoliosis. *J Pediatr Orthop.* 1995;15(5):627-32.
- Canavese F, Turcot K, De Rosa V, de Coulon G, Kaelin A. Cervical spine sagittal alignment variations following posterior spinal fusion and instrumentation for adolescent idiopathic scoliosis. *Eur. Spine J.* 2011;20(7):1141-8.
- Janusz P, Tyrakowski M, Kotwicki T, Siemionow K. Cervical sagittal alignment in Scheuermann disease. *Spine.* 2015;40(23):E1226-32.
- Lenke LG, Betz RR, Harms J, Bridwell KH, Lowe TC, Blanke K. Adolescent idiopathic scoliosis: a new classification to determine extent of spinal arthrodesis. *J Bone Joint Surg Am.* 2001;83(8):1169-81.
- Hardacker JW, Shuford RF, Capicotto PN, Pryor PW. Radiographic standing cervical segmental alignment in adult volunteers without neck symptoms. *Spine.* 1997;22(13):1472-80.
- Kim SW, Kim TH, Bok DH, Jang C, Yang MH, Lee S, et al. Analysis of cervical spine alignment in currently asymptomatic individuals: prevalence of kyphotic posture and its relationship with other spinopelvic parameters. *Spine J.* 2018;18(5):797-810.
- Khalil N, Bizdikian AJ, Bakouny Z, Salameh M, Bou Zeid N, Yared F, et al. Cervical and postural strategies for maintaining horizontal gaze in asymptomatic adults. *Eur Spine J.* 2018;27(11):2700-9.
- Smith JS, Lafage V, Schwab FJ, Shaffrey CI, Protopsaltis T, Protopsaltis T, et al. Prevalence and type of cervical deformity among 470 adults with thoracolumbar deformity. *Spine.* 2014;39(17):E1001-9.
- Ames CP, Smith JS, Eastlack R, Blaskiewicz DJ, Shaffrey CI, Schwab F, et al. Reliability assessment of a novel cervical spine deformity classification system. *J Neurosurg Spine.* 2015;23(6):673-83.
- Abelin-Genevois K, Sassi D, Verdun S, Roussouly P. Sagittal classification in adolescent idiopathic scoliosis: original description and therapeutic implications. *Eur Spine J.* 2018;27(9):2192-202.
- Villavicencio AT, Babuska JM, Ashton A, Busch E, Roeca C, Nelson EL, et al. Prospective, randomized, double-blind clinical study evaluating the correlation of clinical outcomes and cervical sagittal alignment. *Neurosurgery.* 2011;68(5):1309-16.
- Wang DF, Lu SB, Li XY, Shi B, Liu CX, Kong C. The ratio of cervical lordosis to C7 slope represents the reciprocal change between cervical sagittal alignment and global spinal alignment. *J Orthop Surg Res.* 2023;18(1):138.
- Ferrero E, Pesenti S, Blondel B, Jouve JL, Mazda K, Ilharreborde B. Role of thoracoscopy for the sagittal correction of hypokyphotic adolescent idiopathic scoliosis patients. *Eur Spine J.* 2014;23(12):2635-42.
- Sales de Gauzy J, Jouve JL, Ilharreborde B, Blondel B, Accadbled F, Mazda K. Use of the Universal Clamp in adolescent idiopathic scoliosis. *Eur Spine J.* 2014;23(Suppl 4):S446-51.
- La Rosa G, Giglio G, Oggiano L. The Universal Clamp hybrid system: a safe technique to correct deformity and restore kyphosis in adolescent idiopathic scoliosis. *Eur Spine J.* 2013;22(Suppl 6):S823-8.
- Jouve JL, de Gauzy JS, Blondel B, Launay F, Accadbled F, Bollini G. Use of the Universal Clamp for deformity correction and as an adjunct to fusion: preliminary results in scoliosis. *J Child Orthop.* 2010;4(1):73-80.
- Pesenti S, Blondel B, Peltier E, Choufani E, Bollini G, Jouve JL. Interest of T1 parameters for sagittal alignment evaluation of adolescent idiopathic scoliosis patients. *Eur Spine J.* 2016;25(2):424-9.
- Pepke W, Almansour H, Lafage R, Diebo BG, Wiedenhöfer B, Schwab F, et al. Cervical spine alignment following surgery for adolescent idiopathic scoliosis (AIS): a pre-to-post analysis of 81 patients. *BMC Surg.* 2019;19(1):7.
- Pinto EM, Alves J, Teixeira A, Miranda A. Sagittal balance in adolescent idiopathic scoliosis. *Coluna/Columna.* 2019;18(3):182-6.