

HIGH DEGREE SPONDYLOLISTHESIS IN ADULTS: MONOSEGMENTAL REDUCTION AND FIXATION

ESPONDILOLISTESE DE ALTO GRAU EM ADULTOS: REDUÇÃO E FIXAÇÃO MONOSSEGMENTAR

ESPONDILOLISTESIS DE ALTO GRADO EN ADULTOS: REDUCCIÓN Y FIJACIÓN MONOSSEGMENTARIA

EDUARDO HENRIQUE CHIOVATO ABDALA¹, ÉRIKO GONÇALVES FILGUEIRA², LUCIANO DE ALMEIDA FERRER², JOÃO DE SOUZA NASCIMENTO FILHO²

ABSTRACT

Objective: To evaluate a method to reduce high degree spondylolisthesis in adults with monosegmental fixing preserving the adjacent level and the improvement of sagittal balance. **Methods:** A prospective study, with 12 adult patients with high degree spondylolisthesis (III and IV) in adults who underwent surgery by the same team. We included 7 women and 5 men with a mean age of 37 years and lombosciatalgia that had no improvement with conservative treatment. The surgical technique used was total or partial reduction by Spondylolisthesis Reduction Instrument (SRI) system, with instrumentation only in the affected level, thus sparing the adjacent level, associated with 360° fusion. **Results:** The L5-S1 level was involved in nine patients, L4-L5 in two, and VT-S1 in one patient. The isthmus type predominated in nine patients, followed by dysplastic type in two, and one iatrogenic spondylolisthesis. These patients were assessed by the Oswestry scale, which showed a preoperative average of 59% and postoperative average of 12.4% ($P < 0.05$). A significant improvement in the average slip angle from 54.66% to 9.5% (35% to 0%) was found. No major complications such as infection, neurological damage or material breaks were observed. **Conclusion:** The reduction of high degree listhesis instrumenting only the affected level produces good results, with good control of pain and functional improvement of patients. However, a larger follow-up is required to better evaluation.

Keywords: Spine; Spondylolisthesis; Low back pain; Arthrodesis.

RESUMO

Objetivo: Avaliar um método de redução de espondilolistese de alto grau em adultos com fixação monossegmentar, preservando o nível adjacente e a melhora do equilíbrio sagital. **Métodos:** Foram avaliados prospectivamente 12 pacientes adultos portadores de espondilolistese de alto grau (III e IV), submetidos a tratamento cirúrgico pela mesma equipe. Foram incluídos 7 mulheres e 5 homens, com média de idade de 37 anos e quadro de lombociatalgia sem melhora com o tratamento conservador. A técnica cirúrgica utilizada foi redução total ou parcial pelo sistema Spondylolisthesis Reduction Instrument (SRI), instrumentando-se somente o nível acometido e poupando, assim, o nível adjacente, associado à artrodese 360°. **Resultados:** Em nove pacientes o nível L5-S1 foi acometido, L4-L5 em dois pacientes e VT-S1 em um paciente. O tipo ístmico predominou em nove pacientes, o displásico em dois e listese iatrogênica em um paciente. Os pacientes foram avaliados por meio da escala de Oswestry, que mostrou média pré-operatória de 59% e pós-operatória de 12,4% ($P < 0,05$). Houve melhora significativa do ângulo de escorregamento médio de 54,66% para 9,5% (35% a 0%). Não houve complicações como infecção, lesão neurológica ou quebra de material. **Conclusão:** O método de redução da listese de alto grau, instrumentando-se somente o nível acometido, traz bons resultados, com controle do quadro algico e melhora funcional dos pacientes, porém necessita de um follow-up maior para melhor avaliação.

Descritores: Coluna vertebral; Espondilolistese; Dor lombar; Artrodese.

RESUMEN

Objetivo: Evaluar un método de reducción de la espondilolistesis de alto grado en adultos con la fijación monosegmentaria, preservando el nivel adyacente y la mejoría del equilibrio sagital. **Métodos:** Estudio prospectivo de 12 pacientes adultos con espondilolistesis de alto grado (III y IV) sometidos a cirugía por el mismo equipo. Se incluyeron 7 mujeres y 5 hombres con una edad media de 37 años con dolor lumbar sin mejora con el tratamiento conservador. La técnica quirúrgica empleada fue la reducción total o parcial por el sistema Spondylolisthesis Reduction Instrument (SRI), realizando instrumentación sólo en el nivel afectado, conservando los niveles adyacentes, asociados a la artrodese 360°. **Resultados:** En nueve pacientes, el nivel L5-S1 estuvo involucrado, L4-L5 en dos casos y un caso de VT-S1. El tipo ístmico predominó en nueve pacientes, seguido de displasia en dos casos y un caso de listesis iatrogénica. Estos pacientes fueron evaluados utilizando la escala de Oswestry, que mostró un promedio preoperatorio y posoperatorio del 59% al 12,4% ($P < 0,05$). Hubo una mejoría significativa en el ángulo de deslizamiento promedio de 54,66% a 9,5% (35% a 0%). No hubo complicaciones como infecciones, daño neurológico o quiebre de material. **Conclusión:** El método para reducir listesis de alto grado con instrumentación solamente del nivel afectado, trae buenos resultados, con el control del dolor y mejoría funcional de los pacientes; sin embargo, se requiere un seguimiento más largo para que se obtenga una mejor evaluación.

Descriptores: Columna vertebral; Espondilolistesis; Dolor de la región lumbar; Artrodese.

1. Hospital Regional do Paranoá, Spine Surgery Group, Paranoá, DF, Brazil.
2. Hospital de Base do Distrito Federal, Spine Surgery Group, Brasília, DF, Brazil.

Study conducted at the Hospital de Base do Distrito Federal, Brasília, DF, Brazil.

Correspondence: Secretaria de Cirurgia de Coluna, Quadra 02, Conjunto K, Lote 01, Setor Hospitalar. 71.570-130, Paranoá, DF, Brazil. +556133211013 edu_abdala@hotmail.com

INTRODUCTION

Spondylolisthesis, which is characterized by the slippage of one vertebra over another, was first observed by Herbiniaux,¹ a Belgian obstetrician, in 1782, and described by Killian² in 1854.

Five classifications are mentioned in the literature; however, two of them are more commonly used: that of Wiltse et al.,³ who identify five types (Type I: Dysplastic; Type II: Isthmic; Type III: Degenerative; Type IV: Traumatic; Type V: Pathological; and Type VI: Iatrogenic), and that of Marchetti and Bartolozzi,⁴ which is more complete in terms of prognosis and response to treatment. There is also the Meyerding radiological scale, which differentiates the percentage of slippage as Grade I from 0% to 25% (GI), Grade II from 26% to 50% (GII), Grade III from 51% to 75% (GIII), and Grade IV from 76% to 100% (GIV), with GI and GII considered low grade and GIII and GIV considered high grade.⁵

Low and high grade spondylolistheses are totally distinct entities with different treatments. In the high grade type, the greatest concerns are sagittal balance, which can completely alter the biomechanics of the spine, and the risks of neurological lesions and pseudoarthrosis, which can be decisive in the choice of surgical method. In the low grade type, arthrodesis in situ is considered the procedure of choice, as it does not involve the abovementioned concerns.^{6,7}

There is agreement as to the surgical treatment for high grade symptomatic spondylolisthesis,⁷⁻⁹ but the surgical technique to be used is still much debated. There are several types described in the literature with great similarity in the outcomes. Among the different techniques, we can cite posterior arthrodesis in situ, posterior decompression and postero-lateral arthrodesis without reduction, antero-posterior circumferential arthrodesis in situ, a combination of anterior reduction and posterior stabilization, vertebrectomy of L5 with posterior stabilization of L4 to S1, reduction with posterior instrumentation associated with decompression, and posterior arthrodesis.¹⁰⁻¹³

The objective of the study is to report on the surgical treatment of high grade symptomatic spondylolisthesis performed via a posterior approach associated with reduction and monosegment arthrodesis.

MATERIALS AND METHODS

A prospective study was conducted from 2003 to 2010, evaluating 12 patients over the age of 21 years with spondylolisthesis, who did not respond to clinical treatment. There were 5 men and 7 women, with an average age of 37 years (ranging from 21 to 52 years). The average follow-up was 29.1 months (ranging from 6 to 65). All patients had high grade spondylolisthesis, classified as grade III or IV according to the Meyerding classification system.⁵ (Table 1). Based on the Wiltse et al. classification,³ nine patients

were of the Isthmic type, two of the Dysplastic type, and one of the Iatrogenic type.

All patients had lower back pain that worsened with physical exertion. Sciatic pain was present in 10 patients, one of whom had a motor deficit of the root of L5. Seven patients had sensory deficits associated with lower back pain. None of them had cauda equina syndrome.

The criteria for inclusion of patients in the study were: high grade spondylolisthesis, severe lower back pain without improvement after clinical treatment, progression of spondylolisthesis, progressive motor deficit, or cauda equina syndrome. Patients with less than six months of follow up, and those who had been operated on by another surgical team or with another type of surgical technique, were excluded from the study. All were informed of the type of surgery they would undergo, and the associated surgical risks.

The surgical team consisted of three surgeons, always present at all the surgeries, using the same system.

The surgical technique used was total laminectomy associated with a complete or partial reduction of the spondylolisthesis with the S.R.I. system (Spondylolisthesis Reduction Instrument), performing translation and distraction of the segment followed by intersomatic arthrodesis using the P.L.I.F. (Posterior Lumbar Interbody Fusion) technique with a cage or bone graft, associated with postero-lateral arthrodesis with SOCON type (Aesculap®) pedicle screws, with instrumentation of only one level, thereby preserving the adjacent level (Figure 1a). This system enables the reduction of the vertebral body that is uneven due to the translation of the upper vertebra over the lower vertebra with a low risk of radicular trauma (Figures 1b-d). An autologous graft from the iliac crest was used in all patients.

The patients were clinically evaluated using the Oswestry Disability Index (ODI) scale. This evaluation method takes both pain and physical activity into account. The first version was published in 1980,¹⁴ followed by a modification in 1989.¹⁵ The ODI has been validated in numerous countries, facilitating comparison between its results among researchers.¹⁶ Vigatto et al.¹⁷ developed a Brazilian version of the instrument in Portuguese. The values are classified as minimum incapacity (0% to 20%), moderate incapacity (21% to 40%), severe incapacity (41% to 60%), invalid (61% to 80%), and bedridden or exaggerating their symptoms (81% to 100%).¹⁶

The patients were evaluated radiographically for loss of reduction, sacral angle, angle of the slippage, complications from the instrumentation, and consolidation of the arthrodesis. In the pre-operative, immediate post-operative, and late follow-up periods, the Wiltse and Winter method¹⁸ radiographic parameters were used to measure the sacral angle, angle of slippage, and percentage of slippage.

Table 1. Age, percentage of slippage in pre- and post-operative and follow-up.

Patient	Age	Percentage of slippage in pre- and post-op.	Follow-up (months)
1	26	51% - 0%	65
2	33	52% - 0%	41
3	52	54% - 0%	43
4	33	51% - 0%	36
5	28	53% - 10%	8
6	51	52% - 25%	20
7	63	55% - 5%	10
8	49	55% - 0%	12
9	21	55% - 12%	31
10	23	76% - 35%	42
11	24	52% - 12%	36
12	42	55% - 15%	6
Average	37	55% - 9%	29

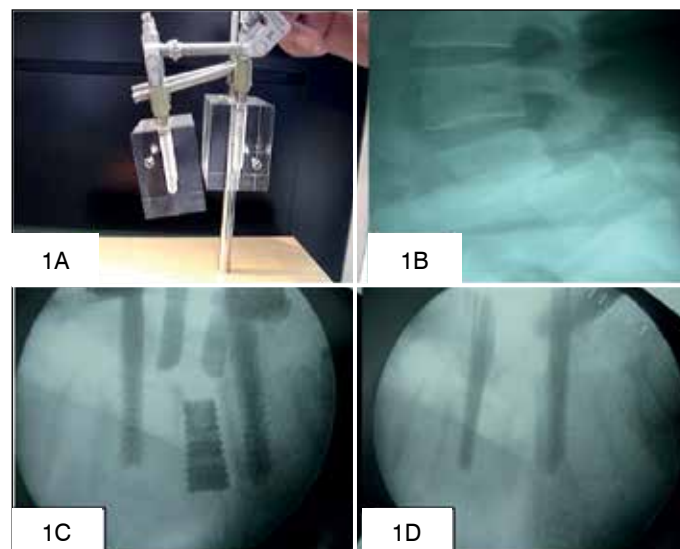


Figure 1. The SRI connected to the pedicle screws (1A). Radiograph with GIII spondylolisthesis (1B). Intraoperative reduction of spondylolisthesis (1C). After reduction 360° arthrodesis was performed (1D).

All patients were mobilized on the second post-operative day, following removal of the suction drain. Neither intra-operative evoked potential nor post-operative orthoses were used.

RESULTS

The Wiltse et al.³ classification was used for the 12 patients in the series: nine with the isthmic type, two with the dysplastic type, and one with the iatrogenic type of spondylolisthesis. The most often affected level was L5-S1 in nine patients, followed by L4-L5 in two patients and VT-S1 in only one patient.

The average initial percentage of slippage was 55% (15% to 76%) and after surgery it dropped to 9.5% (0% to 35%) with $p < 0.05$. The angle of slippage improved from 25° (20° – 35°) to 3° (0° – 7°) in the post-operative period. There was an increase in this angle in only one patient, from 2° in the immediate post-operative period to 7° in the 6th month of follow-up; however, it remained stable over the next two years. This patient had no clinical pain, and both radiography and tomography showed consolidation of the arthrodesis. There was an average improvement of the sacral angle of from 20° (18° – 36°) to 44° (39° – 52°) after surgery, which was maintained in follow-up.

The Oswestry Disability Index (ODI)¹⁵ scale was used both pre- and post-operatively. The pre-operative average was 59% (29.5) (ranging from 92% [46] to 26% [13]), while it was 12.4% (6.2) (ranging from 28% [19] to 0% [0]) post-operatively. This difference is statistically significant, with $p < 0.05$.

All 10 patients showed improvement in radicular pain. There was a great improvement in lower back pain in six patients. Four patients continued to have mild lower back pain related to physical exertion. One patient continued to have lower back pain unrelated to activity and used NSAIDs (Non-steroidal anti-inflammatory drugs) sporadically and physiotherapy. One patient presented an improvement in the L5 motor deficit.

No partial or total lesion of the nerve root was observed during surgery or in the post-operative period. Four years after surgery, one patient developed listhesis in the level above, and underwent a new surgery using the same technique, with good results. An accidental lesion of the dura mater was repaired during surgery, with a good outcome. All 12 patients were monitored by computed tomography after six months of evolution, and all of them showed bone consolidation. None of the patients developed pseudoarthrosis. (Figure 2)

DISCUSSION

High grade spondylolisthesis is a very debilitating clinical condition for the patient. It is a major challenge for the spine surgeon, because of the divergence between the best surgical techniques and the complexity of its classification. As it is not common in our clinics, only a few surgeons have a large case series to report. The objectives of the treatment of high grade symptomatic spondylolisthesis include resolution of lower back pain and improvement of the radicular symptoms associated with arthrodesis of the affected levels and restoration of sagittal balance.^{8,9,19} The current methods for achieving these objectives include a range of surgeries that vary from isolated posterior fusions in situ to aggressive antero-posterior combinations with circumferential procedures, including vertebroctomy.^{7-10,12,13,19}

The level most affected by high grade spondylolisthesis in adults is L5-S1, occurring in rare cases in L5-VT and L4-L5.²⁰ In our case series, the high predominance of level L5-S1 was in agreement with the literature,^{19,20,21} but due to the small number of patients in the studies, reliable comparison is difficult. The Wiltse classification shows that the isthmic type of spondylolisthesis is predominant,^{19,20,21} particularly in adults, which occurred in our statistics. No cases of iatrogenic spondylolisthesis were reported in any of the studies reviewed.

It is known that today, bone fusion in situ is the surgical procedure used in children.^{22,23} However, it has the following problems:

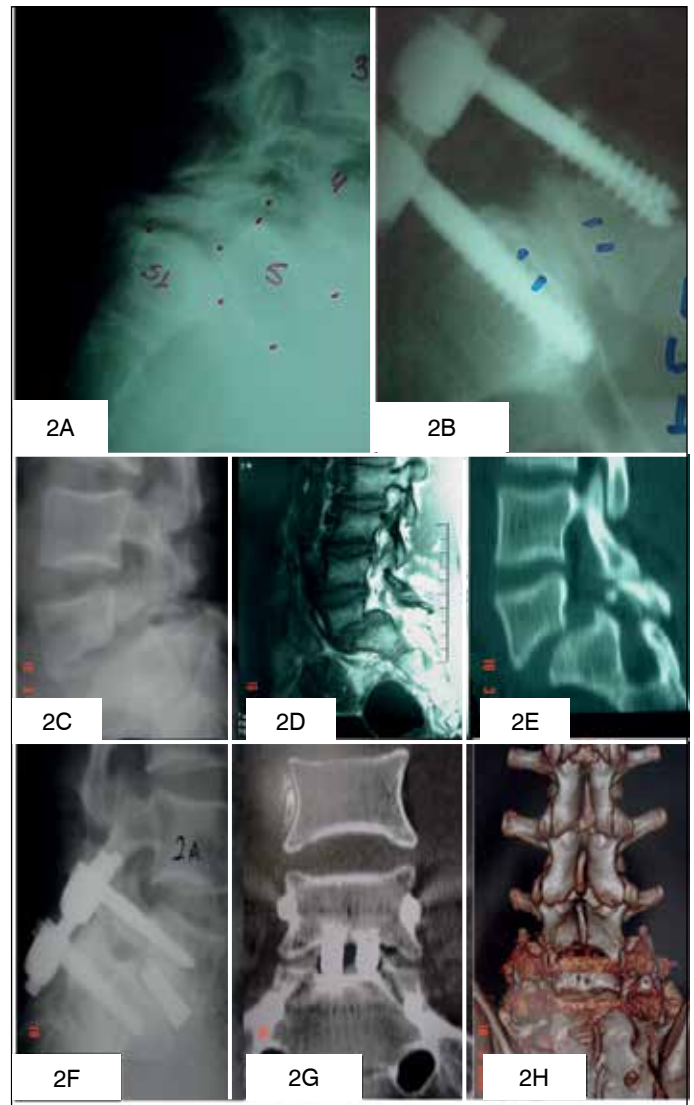

Figure 2. Dysplastic type spondylolisthesis of L5-S1(2A). Fixation of spondylolisthesis with a bone graft in the 1st post-operative year (2B). Pre-operative X-ray with Gill spondylolisthesis (2C). Magnetic resonance.(2D). Computed tomography (2E). Patient in the 2nd post-operative year showing pedicular fixation (2F). Tomography showing consolidated arthrodesis (2G e 2H).

a high rate of pseudoarthrosis, ranging from 0% to 19%; the fact that fusion is extended to the level above it; and the progression of all the parameters of deformity, especially the angle of slippage. On the other hand, instrumented and non-instrumented reductions followed by fusion have been reported with rates of pseudoarthrosis of 0% to 8%.^{22,24}

In adults, posterior fusion in situ is not a viable situation. The inability of most isolated posterior procedures to achieve stabilization of the anterior spine may contribute to the increased rates of pseudoarthrosis, with rates of 17% to 50% being reported.^{10,25} Boos et al.¹⁰ report on 10 patients with high grade spondylolisthesis, 50% of whom had pseudoarthrosis. They conclude that there needs to be anterior support to complement the arthrodesis, and that this was correlated with biomechanical laboratory tests.²⁶

There is still significant controversy concerning reduction in spondylolisthesis in adult patients. This procedure should be considered in patients with evidence of an unstable segment, or when there is a change in sagittal balance.^{8,9,20,21} It has already been recognized that to improve sagittal balance, a partial reduction of the angle of slippage is more important than the percentage of translation.¹¹

Bradford and Brochie¹¹ mention several advantages of reduction in high grade spondylolisthesis, among them, the reduction of the angle of slippage, which allows for neurological decompression, improvement of the lumbosacral sagittal orientation, and an improvement in the patient's overall condition. This partial correction of the lumbosacral angulation not only enables greater anterior compression (improving the probability of arthrodesis), but also improves both the overall sagittal balance and the cosmetic appearance, through the spontaneous correction of thoracic hypokyphosis and lumbar hyperlordosis. When the overall sagittal balance of the patient is improved, this enables erect posture and better biomechanical conditions of the spine. Other advantages are low rates of pseudoarthrosis as compared to arthrodesis in situ, and better neurological decompression. The disadvantages of reduction are the greater surgical time, higher neurological risk, and loss of reduction.^{10,11,19}

Harms²⁷ reported excellent results in 112 patients, using a one-level reduction arthrodesis technique and only L4 for the reduction. He showed an improvement of the angle of slippage in 92.5%, and of the degree in 92%. There was a lower percentage of restoration of the sacral angle as compared to the other parameters, with a 62% improvement, obtaining smaller sacral angles than the norm of 35°. Shufflebarger and Geck²⁸ showed an improvement similar to that of Harms²⁷ in 18 patients using the same technique, with an improvement in the sacral angle, which remained above 35°. One patient evolved with an increase of the progression, stabilizing in six months, and no cases of pseudoarthrosis were reported.

The objective of the procedural technique used here is to restore sagittal balance, making the absorption of the mechanisms of force in the lumbosacral junction more favorable. This procedure also aims to preserve the adjacent disc, thereby reducing new disc degenerations resulting from the arthrodesis of a segment, and maintaining a greater range of movement. In most of the patients, the percentage of slippage was reduced to less than 25% and was associated with 360° arthrodesis. This may explain why no cases of pseudoarthrosis were encountered. Neurological injury, though not found in our case series, is common in patients in whom the grade of spondylolisthesis is reduced; however some factors, such as the surgeon's experience, better exposure with laminectomy, and visualization of the roots during the reduction, may help reduce these risks, ensuring that there is no distraction of the nerve elements.¹⁹

CONCLUSION

The method of high grade spondylolisthesis reduction with instrumentation only at the affected level is a treatment option with good results, with control of the pain profile and functional improvement in patients. It has the advantages of saving levels and improving sagittal balance.

All authors declare no potential conflict of interest concerning this article.

REFERENCES

- Herbiniaux G. Traite sur drivers accouchements laborieux et sur les polypes de la matrice. Brussels: JL Deboubers; 1782.
- Kilian H. Schilderungen neuer becken formen und ihres verhaltens in lebened. Mannheim: Verlag Von Bosserman; 1854.
- Wiltse LL, Newman PH, Macnab I. Classification of spondylolysis and spondylolisthesis. *Clin Orthop Relat Res.* 1976;(117):23-9.
- Marchetti PG, Bartolozzi P. Classification of spondylolisthesis as a guideline for treatment. In: Bridwell KW, de Wald R, editors. *The Textbook of Spinal Surgery.* 2nd ed. Philadelphia: Lippincott-Raven; 1997. p. 1211-54.
- Meyerding H. Spondylolisthesis. *Surg Gynecol Obstet.* 1932;54:371-7.
- Harris IE, Weinstein SL. Long-term follow-up of patients with grade-III and IV spondylolisthesis. Treatment with and without posterior fusion. *J Bone Joint Surg Am.* 1987;69(7):960-9.
- Durrani A, Crawford A. In situ fusion for spondyloptosis. In: Presented at the 67th annual AAOS meeting, Orlando; 2000.
- Boxall D, Bradford DS, Winter RB, Moe JH. Management of severe spondylolisthesis in children and adolescents. *J Bone Joint Surg Am.* 1979;61(4):479-95.
- Bradford DS. Spondylolysis and spondylolisthesis. *Curr Pract Orthop Surg.* 1979;8:12-37.
- Boos N, Marchesi D, Zuber K, Aebi M. Treatment of severe spondylolisthesis by reduction and pedicular fixation. A 4-6-year follow-up study. *Spine (Phila Pa 1976).* 1993;18(12):1655-61.
- Bradford DS, Boachie-Adjei O. Treatment of severe spondylolisthesis by anterior and posterior reduction and stabilization. A long-term follow-up study. *J Bone Joint Surg Am.* 1990;72(7):1060-6.
- Dimar JR, Hoffman G. Grade 4 spondylolisthesis. Two-stage therapeutic approach of anterior vertebrectomy and anterior-posterior fusion. *Orthop Rev.* 1986;15(8):504-9.
- Roca J, Ubierna MT, Cáceres E, Iborra M. One-stage decompression and posterolateral and interbody fusion for severe spondylolisthesis. An analysis of 14 patients. *Spine (Phila Pa 1976).* 1999;24(7):709-14.
- Fairbank JC, Couper J, Davies JB, O'Brien JP. The Oswestry low back pain disability questionnaire. *Physiotherapy.* 1980;66(8):271-3.
- Hudson-Cook N, Tomes-Nicholson K, Breen A. Revised Oswestry disability questionnaire. In: Roland M, Jenner JR, editors. *Back pain: new approaches to rehabilitation and education.* Manchester: Manchester University Press; 1989. p. 187-204.
- Fairbank JC, Pynsent PB. The Oswestry Disability Index. *Spine (Phila Pa 1976).* 2000;25(22):2940-52.
- Vigatto R, Alexandre NM, Correa Filho HR. Development of a Brazilian Portuguese version of the Oswestry Disability Index: cross-cultural adaptation, reliability, and validity. *Spine (Phila Pa 1976).* 2007;32(4):481-6.
- Wiltse LL, Winter RB. Terminology and measurement of spondylolisthesis. *J Bone Joint Surg Am.* 1983;65(6):768-72.
- Boachie-Adjei O, Do T, Rawlins BA. Partial lumbosacral kyphosis reduction, decompression, and posterior lumbosacral transfixation in high-grade isthmic spondylolisthesis: clinical and radiographic results in six patients. *Spine (Phila Pa 1976).* 2002;27(6):E161-8.
- DeWald CJ, Vartabedian JE, Rodts MF, Hammerberg KW. Evaluation and management of high-grade spondylolisthesis in adults. *Spine (Phila Pa 1976).* 2005;30(Suppl 6):S49-59.
- Poussa M, Schlenzka D, Seitsalo S, Ylikoski M, Hurri H, Osterman K. Surgical treatment of severe isthmic spondylolisthesis in adolescents. Reduction or fusion in situ. *Spine (Phila Pa 1976).* 1993;18(7):894-901.
- Burkus JK, Lonstein JE, Winter RB, Denis F. Long-term evaluation of adolescents treated operatively for spondylolisthesis. A comparison of in situ arthrodesis only with in situ arthrodesis and reduction followed by immobilization in a cast. *J Bone Joint Surg Am.* 1992;74(5):693-704.
- Dandy DJ, Shannon MJ. Lumbo-sacral subluxation. (Group 1 spondylolisthesis). *J Bone Joint Surg Br.* 1971;53(4):578-95.
- Lance EM. Treatment of severe spondylolisthesis with neural involvement. A report of two cases. *J Bone Joint Surg Am.* 1966;48(5):883-91.
- Abdu WA, Wilber RG, Emery SE. Pedicular transvertebral screw fixation of the lumbosacral spine in spondylolisthesis. A new technique for stabilization. *Spine (Phila Pa 1976).* 1994;19(6):710-5.
- Shirado O, Zdeblick TA, McAfee PC, Warden KE. Biomechanical evaluation of methods of posterior stabilization of the spine and posterior lumbar interbody arthrodesis for lumbosacral isthmic spondylolisthesis. A calf-spine model. *J Bone Joint Surg Am.* 1991;73(4):518-26.
- Harms J. True spondylolisthesis reduction and monosegmental fusion in spondylolisthesis. In: Bridwell K, Dewald R, editors. *The textbook of spinal surgery.* 2nd ed. Philadelphia: Lippincott-Raven; 1997. p. 1337-47.
- Shufflebarger HL, Geck MJ. High-grade isthmic dysplastic spondylolisthesis: monosegmental surgical treatment. *Spine (Phila Pa 1976).* 2005;30(Suppl 6):S42-8.