

# ENDOSCOPIC TREATMENT OF PARS INTERARTICULARIS SPONDYLOLYSIS: A CASE REPORT

TRATAMENTO ENDOSCÓPICO DA ESPONDILÓLISE DA PARS INTERARTICULARIS: RELATO DE CASO

TRATAMIENTO ENDOSCÓPICO DE ESPONDILÓLISIS DE LA PARS INTERARTICULARIS: REPORTE DE CASO

MARCELO BOTELHO SOARES DE BRITO<sup>1,2,3</sup> , BRUNO BRASIL DO COUTO<sup>2,3</sup> , GEORGE PEDRO LIMA FEITOSA<sup>1</sup> , THIAGO QUEIROZ SOARES<sup>1,4,5</sup> ,  
FERNANDO FLORES DE ARAÚJO<sup>1,4,5</sup> , EDGAR TAKAO UTINO<sup>1</sup> , FERNANDA WIRTH<sup>5</sup> , JOÃO PAULO MACHADO BERGAMASCHI<sup>1,4,5</sup> 

1. Universidade de São Paulo, Ribeirão Preto Medical School (USP-RP), Specialization Course in Endoscopic Spine Surgery, Ribeirão Preto, SP, Brazil.
2. Clínica Articulare, Belém, Pará, Brazil.
3. Hospital Porto Dias, Belém, Pará, Brazil.
4. Clínica Atuali Spine Care, São Paulo, SP, Brazil.
5. Atuali Academy, São Paulo, SP, Brazil.

## ABSTRACT

The treatment for symptomatic pars interarticularis spondylolysis remains controversial. Since most affected patients are young, minimally invasive techniques, have been reported to minimize tissue damage and provide an early return to daily activities. We report a clinical case of a patient with a lesion of the pars, a lesion of the contralateral pedicle, and a herniated disc who underwent surgical treatment by endoscopy one time. Due to the low level of evidence of the case report/series, further studies should be carried out to confirm this hypothesis. **Level of Evidence IV; Case Report.**

**Keywords:** Hernia; Endoscopic Surgical Procedure; Spondylolysis; Spine; Discectomy, Percutaneous.

## RESUMO

O tratamento da espondilólise da pars interarticularis sintomática continua controverso. Em virtude da maioria dos pacientes acometidos serem jovens, técnicas minimamente invasivas têm sido reportadas para minimizar o dano tecidual e proporcionar o retorno precoce às atividades diárias. Relatamos um caso clínico de um paciente com lesão da pars, lesão do pedículo contralateral e hérnia discal que foi submetido a tratamento cirúrgico por endoscopia em 1 só tempo. Em virtude de o nível de evidência de relato/série de caso ser baixo, mais estudos deverão ser realizados para confirmar essa hipótese. **Nível de Evidência IV; Relato de Caso.**

**Descritores:** Hérnia; Procedimentos Cirúrgicos Endoscópicos; Espondilólise; Coluna Vertebral; Discotomia Percutânea.

## RESUMEN

El tratamiento de la espondilólisis de la pars interarticularis sintomática sigue siendo controvertido. Debido a que la mayoría de los pacientes afectados son jóvenes, se ha comprobado que las técnicas mínimamente invasivas minimizan el daño tisular y brindan un regreso temprano a las actividades diarias. Presentamos un caso clínico de un paciente con lesión de la pars, lesión del pedículo contralateral y hernia discal que fue intervenido quirúrgicamente por endoscopia en 1 tiempo. Debido al bajo nivel de evidencia del reporte/serie de casos, se deben realizar más estudios para confirmar esta hipótesis. **Nivel de Evidencia IV; Reporte de Caso.**

**Descriptorios:** Hernia; Procedimientos Quirúrgicos Endoscópicos; Espondilólisis; Columna Vertebral; Discectomía Percutánea.

## INTRODUCTION

Lumbar spondylolysis occurs due to stress fractures with subsequent pseudoarthrosis of the *pars interarticularis*<sup>1</sup>. It is a common cause of lower back pain in children, adolescents, and young adults<sup>2</sup>, with an approximate occurrence of 3-10% in the general population and 6% in adults<sup>3</sup>. The incidence in young adults practicing physical activities varies from 15-47%<sup>4-6</sup>.

The vast majority of patients show a good response to conservative treatment, which consists of using medications for pain relief, avoiding impact sports, strengthening the core muscles, and using

lumbar braces for analgesia for 3-6 months<sup>7,8</sup>. Surgical treatment is rare and indicated in patients with persistent pain without response to conservative treatment<sup>9</sup>.

Surgical treatment options have evolved significantly from arthrodesis, with or without the removal of posterior elements, to the introduction of direct repair techniques of the *pars*<sup>8</sup>. As most patients undergoing direct repair surgery of the *pars* are young adults<sup>10</sup>, it becomes essential to seek surgical techniques that cause less damage to the posterior musculature of the lumbar region, with a consequent early return to daily activities<sup>11</sup>.

Study conducted by the Clínica Atuali, São Paulo, SP, Brazil.

Correspondence: Marcelo Botelho Soares de Brito. Clínica Articulare, 791, Senador Lemos Ave, Room 305, Belém, PA, Brazil. 66050-005. britombs@gmail.com



Based on this premise, we applied the use of spinal endoscopy in the surgical treatment of a patient with foraminal lumbar disc herniation, lesion of the *pars interarticularis* and stress fracture of the contralateral pedicle.

### CASE REPORT

The patient signed the informed consent form (ICF), and the report was approved by the Ethics Committee (CAAE 70416223.8.0000.5487, opinion number 6.339.106).

The male patient, 30 years old, had intermittent lower back pain since adolescence. In adult life, it refers to the appearance of recurrent left-sided lumbosciatalgia, with significant worsening in the last three months. Conservative treatment was carried out for four months and was not successful. It consisted of rest, analgesia, analgesic physiotherapy, and muscle strengthening. On physical examination, he presented with lower back pain radiating to the left lower limb (LLE), paresthesia in the L4 territory on the left, without strength deficit.

The Visual Analog Scale (VAS) for pain showed 8/10 for pain in the lumbar region and 8/10 for the LLE. The Oswestry Disability Index (ODI) scored 40%, which falls under moderate disability.

Lumbar spine X-rays showing grade I spondylolisthesis without signs of instability on dynamic X-rays at the L4-L5 level (Figure 1A). The computed tomography (CT) scan of the lumbar spine showed lysis of the *pars interarticularis* of L4 on the right and fracture of the contralateral pedicle in the same vertebra (Figure 1B). Magnetic resonance imaging (MRI) showed left foraminal disc herniation at the L4-L5 level and a grade I spondylolisthesis (Figure 1C).

Surgical treatment was then scheduled, with left transforaminal lumbar endoscopic discectomy, with percutaneous fixation at the same surgical time with a traction screw in the left pedicular position and translaminar on the right.

The patient was placed under general anesthesia and positioned prone. The first step was the passage of the percutaneous pedicle screw into the L4 pedicle after marking the entry point by radioscopy, inserting the guide wire, and subsequently, the 4.5 mm diameter cannulated cancellous screw, partial thread.

The next step was the insertion of the guide wire for the passage of the translaminar screw. Under direct endoscopic visualization, we prepared the entry point of the guide wire on the lower edge of the ipsilateral lamina with a drill. The insertion of the guide wire and the drill is performed with the aid of radioscopy. We performed the fixation of the *pars* with a partially threaded 4.5 mm diameter spongy cannulated screw. The passage of the guide wire and the cannulated screw were made according to Buck's technique<sup>2</sup>, with an entry point approximately 10 mm lateral to the spinous process, at the caudal edge of the lamina, with the radioscopy positioned in profile, angling 30 degrees laterally in the sagittal plane, towards the ipsilateral pedicle, crossing the defect of the *pars interarticularis*.

Subsequently, the defect point was marked, and a small incision was made for positioning the endoscope until the lesion of the *pars*

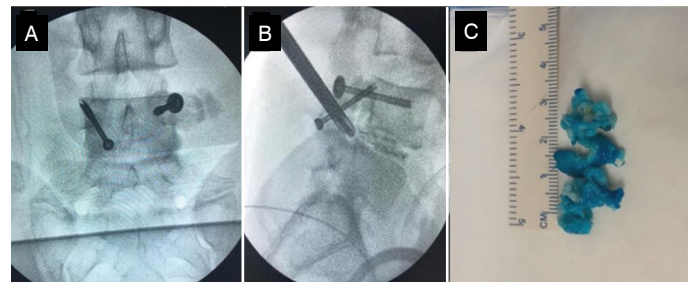
*interarticularis* was visualized. All fibrotic tissue from the pseudoarthrosis was removed with the aid of a drill to remove the sclerotic bone until a bleeding bone surface was visible.

A heterologous bone graft (Bonalive®) was added to the previously prepared bone region, with subsequent tightening of the screw and removal of the guide wire. After radioscopic control, a good position of the cancellous screw was observed, with the thread completely crossing the defect (Figure 2A). In the final stage of the procedure, transforaminal endoscopic access was performed using the *outside-in* technique on the left, with prior chromo-discography (Figure 2B), foraminoplasty with a drill, and removal of the extruded disc fragment (Figure 2C).

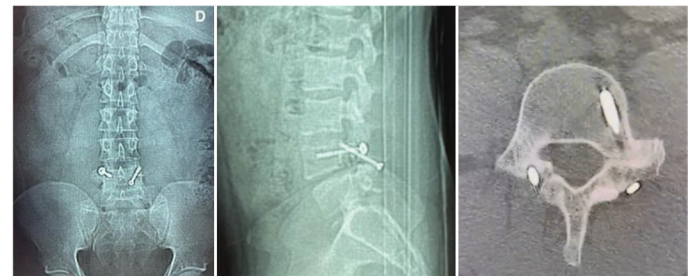The patient was discharged from the hospital the next day with permission to ambulate and use a lumbar belt for 30 days. The patient reported improved pain in the immediate postoperative period, with a lumbar VAS of 3/10 and a VAS in the left lower limb of 1/10.

After three months of follow-up, the X-rays showed normally positioned screws, and the CT scan showed complete consolidation of the pedicular lesion and partial consolidation of the *pars* lesion (Figure 3).

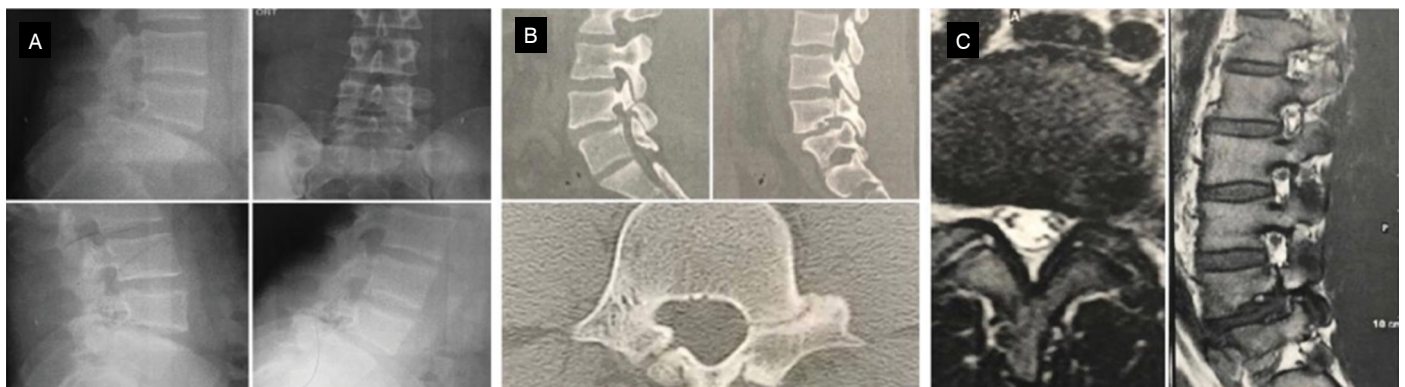In the immediate postoperative period, the patient reported an excellent MacNab satisfaction index maintained six months postoperatively.



**Figure 2.** Fluoroscopy showing the pedicle screw and the translaminar screw (A); intraoperative fluoroscopy showing the positioning of the endoscope working cannula and the chromo-discography (B); removed disc herniation fragments (C).



**Figure 3.** Postoperative X-rays and axial CT scan of the lumbar spine with three months of follow-up.



**Figure 1.** X-rays of the lumbar spine in anteroposterior (AP) view, profile, and dynamic in flexion and extension (A); sagittal and axial cuts of the preoperative lumbar CT (B); T2-weighted axial cut and T1-weighted sagittal cut of the preoperative MRI (C).

## DISCUSSION

Due to the good response to conservative treatment, surgery for the treatment of symptomatic spondylolysis is not often used. As frequent surgical treatment options, we have arthrodesis and direct repair of the *pars interarticularis*<sup>12</sup> lesion.

Arthrodesis presents a good overall result, with the disadvantage of loss of movement in the affected segment. It is also a more invasive surgery with a higher risk of complications<sup>12</sup>.

Direct repair of the *pars interarticularis* lesion has been widely used for the surgical treatment of spondylolysis in young patients, with the advantage of restoring normal anatomy, eliminating painful pseudoarthrosis, and maintaining movement of the affected segment<sup>13</sup>. Several techniques have been described for the repair of the *pars interarticularis*: screw through the defect and bone graft, known as Buck's technique<sup>2</sup>; sublaminar wires<sup>14</sup> and techniques with screws and hooks<sup>15</sup>. Another more recently described technique employs pedicle screws to anchor a cable that brings the defect closer to the *pars*. Initially described by Songer and Rovin<sup>16</sup>, this technique has the advantage of reducing the *pull-out* due to the support that the pedicle screw provides to the structure assembly. Direct repair techniques based on pedicle screw construction show the best clinical results, followed by the Buck technique<sup>2,17</sup>.

Buck described his technique for fixing the *pars* in 1970 with 93% clinical success. The patients were positioned in a prone position to decrease the lumbar lordosis. After a median incision centered on the spinous processes and with the dissection of all the paravertebral musculature, the defect of the *pars* was located, with the cleaning of the lamina and removal of all the fibrous tissue from the lesion until a raw surface was created. Under direct visualization, a hole was made in the lower edge of the blade with cranial, superior, and slightly lateral orientation to cross the defect. After that, the screw was inserted, not fully tightened, and an autologous graft taken from the iliac crest was placed in the defect area, finishing with the complete tightening of the screw. The musculature, fascia, and skin were closed, and the suction drain was positioned with guidance for the patient to remain hospitalized and in a horizontal position for 3 to 4 days<sup>2</sup>.

The vast majority of patients who require surgical treatment for lumbar spondylolysis are adolescents and young adults. Many participate in sports activities and must return to sports practice as soon as possible<sup>10,11</sup>. Due to the need for less aggressive techniques, new technologies have been incorporated into the surgical treatment of this pathology. Tian et al. described a case report with a good outcome of the repair of the *pars interarticularis* in a 26-year-old patient, using robot-assisted technology (TiRobot System®), and the screw trajectory determined intraoperatively through three-dimensional radiographic images<sup>18</sup>.

In the early stages of spinal endoscopy, its indication was basically for the decompression of discal soft tissues through Kambin's triangle<sup>19</sup>. With the advent of new instruments and the development of endoscopic techniques, there has also been an expansion of its indications and the diseases that can be treated by this approach<sup>20,21</sup>. The improvement in optical instruments, drills, and the development of numerous instruments have made the indications for the endoscopic approach reach pathologies for which it was previously contraindicated, such as calcified disc herniation and canal stenosis<sup>21</sup>. One pathology that still presents little approach by endoscopic surgery is lumbar spondylolysis for fixation of the lesion of the *pars interarticularis*. There are four steps for the treatment of this pathology that can be performed endoscopically: 1) percutaneous placement of cannulated screws; 2) identification of the defect; 3) curettage of the defect; 4) positioning of the graft<sup>22</sup>.

In the present case, we show a patient with a history of lower

back pain since adolescence, diagnosed with spondylolysis of the *pars interarticularis* on the right and a contralateral pedicle lesion, both probably due to the same mechanism, an unhealed stress fracture. In adult life, he developed a left foraminal lumbar disc herniation at the same level. When surgical treatment via endoscopic approach for foraminal disc herniation was proposed, it was possible to treat all three pathologies simultaneously using an ultra-minimally invasive method, which provided benefit to the patient and early return to their activities. The passage of the cannulated screw in the L4 pedicle lesion on the left was done without the need for endoscopy through the placement of a guide wire percutaneously in the pedicle<sup>22</sup>.

The following steps were performed using a transforaminal endoscope with a 3.6mm working channel. The choice of this endoscope is appropriate for performing the transforaminal technique and removal of the disc herniation, for using the drill at the entry point for placing the guide wire of the translaminar screw, for the cruentization of the lesion of the *pars* and placement of the heterologous graft. A possible modification to the technique would be the use of a stenosis endoscope, whose 7mm working channel would allow the screw to pass through it. The clinical outcome of the described case was satisfactory, with the patient reporting significant improvement in the pain pattern already in the immediate postoperative period, in addition to an Excellent MacNab score.

Few studies have been conducted to investigate the treatment of *pars interarticularis* lesions using the endoscopic technique, and the vast majority have been based on the video-assisted technique. Higashino et al. described a series of three cases using video-assisted surgery to treat the *pars* lesion, using a 2cm incision through which muscle dilators and the tubular retractor were inserted<sup>11</sup>.

Soliman reported a sequence of seven cases of bilateral spondylolysis treated using spinal endoscopy with the biportal technique and fixed with 4.5mm percutaneous cannulated screws without the use of graft at the failure site. A portal was used for the passage of the endoscope, and another portal for the passage of surgical instruments, to clean the defect area and make the entry point for the cannulated screw. He described excellent results in six patients and good results in one<sup>23</sup>. Jin et al. described a sequence of 12 cases of spondylolysis treated by assisted endoscopic technique, pedicle screw fixation, and autologous iliac crest graft. At the end of 3 months, only one case resulted in non-union, and the rest showed improvement in the results of the VAS, quality of life questionnaire (SF-36), and ODI<sup>24</sup>.

The endoscopic technique appears promising in direct *pars* repair surgical treatment, with or without other associated pathologies. As shown in the case report, the use of spinal endoscopy can identify the lesion, prepare the pseudoarthrosis site for bone graft placement, locate and prepare the entry point for the cannulated screw, and, when using a 7mm working channel, can even be used for passing the screw over the guide wire. In the presence of other pathologies, such as herniated discs, treatment can be performed in a single surgical session.

## CONCLUSION

Endoscopy of the spine presents favorable conditions for the direct repair of the *pars interarticularis* lesion. It is minimally invasive and allows for quick recovery and early return to activities. However, more studies should be conducted to confirm such benefits compared to other techniques.

---

Todos os autores declaram não haver nenhum potencial conflito de interesses referente a este artigo.

---



---

**CONTRIBUTIONS OF THE AUTHORS:** Each author contributed individually and significantly to the development of this article. MBSB, BBC, GPLF, JPMB: planning and execution of the surgery; TQS, FFA, ETU: data analysis and manuscript preparation; JPMB, MBSB, FW: article review and submission to the journal.

---

## REFERENCES

1. Wiltse LL, Widell E, Jackson DW. Fatigue fracture: the basic lesion is isthmic spondylolysis. *J Bone Joint Surg Am.* 1975;57(1):17-22.
2. Buck JE. Direct repair of the defect in spondylolisthesis. Preliminary report. *J Bone Joint Surg Br.* 1970;52(3):432-7.
3. Hensinger RN. Spondylolysis and spondylolisthesis in children and adolescents. *J Bone Joint Surg Am.* 1989;71(7):1098-107.
4. Rossi F, Dragoni S. Lumbar spondylolysis: occurrence in competitive athletes. Updated achievements in a series of 390 cases. *J Sports Med Phys Fitness.* 1990;30(4):450-2.
5. Micheli LJ, Wood R. Back pain in young athletes. Significant differences from adults in causes and patterns. *Arch Pediatr Adolesc Med.* 1995;149(1):15-8. doi: 10.1001/archpedi.1995.02170130017004.
6. Soler T, Calderón C. The prevalence of spondylolysis in the Spanish elite athlete. *Am J Sports Med.* 2000;28(1):57-62. doi: 10.1177/03635465000280012101.
7. Hayden JA, Ogilvie R, Kashif S, Singh S, Boulos L, Stewart SA, Wieland LS, Jesus-Moraleida FR, Saragiotto BT, Yamato TP, Zoete A, Bülow K, Almeida de Oliveira L, Bejarano G, Cancelliere C. Exercise treatments for chronic low back pain: a network meta-analysis. *Cochrane Database Syst Rev.* 2023 Jun 7;2023(6):CD015608. doi: 10.1002/14651858.CD015608. PMID: PMC10250000.
8. Debnath UK. Lumbar spondylolysis - Current concepts review. *J Clin Orthop Trauma.* 2021;21:101535. doi: 10.1016/j.jcot.2021.101535.
9. Pedersen AK, Hagen R. Spondylolysis and spondylolisthesis. Treatment by internal fixation and bone-grafting of the defect. *J Bone Joint Surg Am.* 1988;70(1):15-24.
10. Debnath UK, Freeman BJC, Gregory P, de la Harpe D, Kerslake RW, Webb JK. Clinical outcome and return to sport after the surgical treatment of spondylolysis in young athletes. *J Bone Joint Surg Br.* 2003;85(2):244-9. doi: 10.1302/0301-620x.85b2.13074.
11. Higashino K, Sairyo K, Katoh S, Sakai T, Kosaka H, Yasui N. Minimally invasive technique for direct repair of the pars defects in young adults using a spinal endoscope: a technical note. *Minim Invasive Neurosurg.* 2007;50(3):182-6. doi: 10.1055/s-2007-982511.
12. Lim MR, Yoon SC, Green DW. Symptomatic spondylolysis: diagnosis and treatment. *Curr Opin Pediatr.* 2004;16(1):37-46. doi: 10.1097/00008480-200402000-00008.
13. Menga EN, Kebaish KM, Jain A, Carrino JA, Sponseller PD. Clinical results and functional outcomes after direct intralaminar screw repair of spondylolysis. *Spine (Phila Pa 1976).* 2014;39(1):104-10. doi: 10.1097/BRS.0000000000000043.
14. Nicol RO, Scott JH. Lytic spondylolysis. Repair by wiring. *Spine (Phila Pa 1976).* 1986;11(10):1027-30. doi: 10.1097/00007632-198612000-00011.
15. Tokuhashi Y, Matsuzaki H. Repair of defects in spondylolysis by segmental pedicular screw hook fixation. A preliminary report. *Spine (Phila Pa 1976).* 1996;21(17):2041-5. doi: 10.1097/00007632-199609010-00023.
16. Songer MN, Rovin R. Repair of the pars interarticularis defect with a cable-screw construct. A preliminary report. *Spine (Phila Pa 1976).* 1998;23(2):263-9. doi: 10.1097/00007632-199801150-00023.
17. Mohammed N, Patra DP, Narayan V, Savardekar AR, Dossani RH, Bollam P, et al. A comparison of the techniques of direct pars interarticularis repairs for spondylolysis and low-grade spondylolisthesis: a meta-analysis. *Neurosurg Focus.* 2018;44(1):E10. doi: 10.3171/2017.11.FOCUS17581.
18. Tian W, Zhang Q, Han XG, Yuan Q, He D, Liu YJ. Robot-assisted direct repair of spondylolysis: A case report. *Medicine (Baltimore).* 2020;99(4):e18944. doi: 10.1097/MD.00000000000018944.
19. Kambin P, Sampson S. Posterolateral percutaneous suction-excision of herniated lumbar intervertebral discs. Report of interim results. *Clin Orthop Relat Res.* 1986;(207):37-43.
20. Kim M, Kim HS, Oh SW, Adsul NM, Singh R, Kashlan ON, et al. Evolution of Spinal Endoscopic Surgery. *Neurospine.* 2019;16(1):6-14. doi: 10.14245/ns.1836322.161.
21. Butler AJ, Alam M, Wiley K, Ghasem A, Rush I, Wang JC. Endoscopic Lumbar Surgery: The State of the Art in 2019. *Neurospine.* 2019;16(1):15-23. doi: 10.14245/ns.1938040.020.
22. Yoshii T, Hirai T, Yamada T, Sumiya S, Matsumoto R, Kato T, et al. Lumbosacral pedicle screw placement using a fluoroscopic pedicle axis view and a cannulated tapping device. *J Orthop Surg Res.* 2015;10:79. doi: 10.1186/s13018-015-0225-5.
23. Soliman HM. Irrigation endoscopic assisted percutaneous pars repair: technical note. *Spine J.* 2016;16(10):1276-81. doi: 10.1016/j.spinee.2016.06.009.
24. Jin M, Zhang J, Shao H, Liu J, Zhao T, Huang Y. Percutaneous endoscopic-assisted direct repair of pars defect without general anesthesia could be a satisfying treatment alternative for a young patient with symptomatic lumbar spondylolysis: a technique note with case series. *BMC Musculoskelet Disord.* 2020;21(1):340. doi: 10.1186/s12891-020-03365-4.