

PERCUTANEOUS FUSION OF LUMBAR FACET WITH BONE ALLOGRAFT

FUSÃO DE FACETA LOMBAR POR VIA PERCUTÂNEA COM ALOENXERTO ÓSSEO

FUSIÓN FACETARIA LUMBAR POR VÍA PERCUTÁNEA CON ALOINJERTO ÓSEO

FÉLIX DOLORIT VERDECIA¹, HIRAM MARTINEZ MEDINA²

ABSTRACT

Objective: To assess the evolution of the cases treated with percutaneous facet fusion with bone allograft in lumbar facet disease. **Method:** Between 2010 and 2014, 100 patients (59 women and 41 men) diagnosed with lumbar facet disease underwent surgery. **Results:** The lumbar facet fusion with bone allograft shows good clinical results, is performed on an outpatient basis, and presents minimal complications and rapid incorporation of the patient to the activities of daily living. **Conclusions:** The lumbar facet fusion with bone allograft appears to be an effective treatment for lumbar facet disease.

Keywords: Spinal fusion; Lumbar vertebrae; Bone screws.

RESUMO

Objetivo: Avaliar a evolução dos casos tratados com a fusão de faceta por via percutânea com aloenxerto ósseo na doença facetária lombar. **Método:** Entre 2010 e 2014, 100 pacientes (59 mulheres e 41 homens) com diagnóstico de doença facetária lombar foram submetidos à cirurgia. **Resultados:** A fusão de faceta lombar com aloenxerto ósseo mostra bons resultados clínicos, é realizada em ambulatório, apresenta complicações mínimas e incorporação rápida do paciente às atividades da vida diária. **Conclusões:** A fusão facetária percutânea com aloenxerto ósseo parece ser um tratamento eficaz para a doença de faceta lombar.

Descritores: Fusão vertebral; Vértebras lombares; Parafusos ósseos.

RESUMEN

Objetivo: Valorar la evolución de los casos tratados con fusión facetaria por vía percutánea con aloinjerto óseo en la enfermedad facetaria lumbar. **Método:** Entre los años 2010 y 2014 se intervinieron 100 pacientes (59 mujeres y 41 hombres) con diagnóstico de enfermedad facetaria lumbar. **Resultados:** La fusión facetaria lumbar con aloinjerto óseo muestra buenos resultados clínicos, se realiza de forma ambulatoria, presenta mínimas complicaciones y una rápida incorporación del paciente a sus actividades diarias. **Conclusiones:** La fusión facetaria lumbar con aloinjerto óseo parece ser un tratamiento eficaz para la enfermedad facetaria lumbar.

Descriptores: Fusión vertebral; Vértebras lumbares; Tornillos óseos.

INTRODUCTION

It is now recognized that the incidence of facet disease is high, with a prevalence that ranges from 7.7% to 75% of the general population.¹

As early as the beginning of the last century, Goldwait pointed out the importance of the lumbar facet joint in the functioning of the lumbar spine², and in 1933, Ghormley introduced the term "lumbar facet joint syndrome" for the first time.³

The complexity of the lumbar pain, its diverse origins in the different structures that make up the spinal canal, and the characteristics of each level, require a comprehensive approach to the study and treatment of each pathological condition. It also requires the physician (preferably a spine specialist), based on his or her anatomical and biomechanical knowledge, to be able to search for the generator of the pain that the patient presents, and be able to effect a successful treatment.

Although some authors affirm that the diagnosis of facet joint disease is done by a process of elimination,⁴ we believe that when we perform a thorough medical history, including complete, high-resolution radiological studies (simple X-ray, computed tomography, in all its forms, and nuclear magnetic resonance imaging), we can

come closer to the diagnosis, which in our opinion, is confirmed when we perform three fluoroscopy-guided facet joint blocks, two weeks apart, and when we see an improvement of more than 75% in the symptoms of pain.

The specific treatment of pain of facet joint origin did not emerge until the 1970s, and since then, various therapeutic methods, both medical and surgical, have been used in an attempt to resolve this problem. We believe that as an initial alternative, conservative treatment should be used, with both pharmacological means and well-established, controlled rehabilitation for a minimum period of three months. Only when these are no longer effective is more invasive management justified, such as injection of anesthetic and inflammatory substances, various methods of denervation of the joint surface with a destructive agent such as phenol, and the use of radiofrequency electrodes. However, all these techniques have the drawback of regeneration of the nerve terminals of the Luschka joint, leading to the recurrence of the pain.

From the anatomical and physiological points of view, the lower levels of the lumbar spine are subjected to higher loads, and the joint surfaces of segments have to bear much of the axial load,

1. International Neurosurgery Institute, Larkin Hospital, Miami, Florida, USA.

2. Hospital Dalinde, Mexico DF, Mexico.

Study conducted at the International Neurosurgery Institute of the Larkin Hospital, Miami, Florida, USA.

Correspondence: International Neurosurgery Institute Larkin Hospital, Miami, Florida. dolorit58@hotmail.com

especially in flexion and rotation, making them more vulnerable to injury and pain.⁵ For this reason, in search of a remedy for this this abnormal movement of the degenerated segment, arthrodesis with plate and screws has been suggested, either in open surgeries or via the percutaneous approach. Our team has suggested achieving the merger and the correction of these abnormal movements through the percutaneous placement of a bone allograft in the joint, with a view of the joint, using a minimally invasive procedure. In theory, this would alleviate the pain caused by the abnormal mobility of the arthrotic joint.

METHOD

The population of this study consisted of 100 consecutive patients seen at the International Neurosurgery Institute of the Larkin Hospital in Miami, Florida, between January 2010 and January 2014. All the patients had been diagnosed with lumbar facet joint disease, based on rigorous clinical and radiological criteria, and by facet blocks. All the cases were subjected to at least the months of conservative treatment before deciding the surgical procedure.

The age range was between 40 and 90 years.

The facet blocks were made with a mixture of 9 cc Marcaine 0.25% plus 1 cc Depomedrol 40 mg. The frequency was 3 blocks, two weeks apart, and taking as a positive outcome a 75% improvement in the pain, all guided by fluoroscopy.

The fusion was performed using a surgical kit designed mainly part by the medical team. The allograft bone is cylindrical in shape (8 mm in length, 5 mm at the base and 4.8 mm at the tip) and is provided by the University of Miami Tissue Bank, which follows all the safety standards. The surgery is performed via the percutaneous approach, with fluoroscopic control. Anesthesia was by sedation with local anesthesia, lidocaine 1%, and all the patients had intraoperative neuromonitoring.

The evolution of the patients was followed up according to a protocol drawn up in advance and signed by the patients to signify their agreement. In the follow-up visits, Oswestry's functional scale was used, and the pain was measured using the VAS scale, which applied in the initial consultation, as soon as the patient was admitted to surgical intervention, in the immediate postoperative period, at one month, three and six months, and then every year. The majority of follow-ups were done by telephone or home visit.

For the data processing and analysis, the data were entered into a percentage system.

RESULTS AND DISCUSSION

The sample consisted of 100 patients. The most frequent age was between 56 and 70 years, in 46%. It is significant that 8% of the cases were over the age of 85. (Figure 1)

In the distribution by sex, there was a predominance of females with a 59%. This is consistent with other articles⁶. (Figure 2)

In terms of the location of the pain, 60% only presented lumbar pain without irradiation, and the other 42% had lumbar pain with irradiation; 20% in the gluteal region, 8% in the groin and the 12% at the back of the leg. (Figure 3) Similar results have been found by other authors.⁷⁻¹¹

In the distribution according to the classification of facet joint degeneration by MRI, 55% corresponded to the grade II. It should be pointed out that that no patient with grade 0 underwent surgery. (Figure 4)

The patient's response to the facet blocks was positive. 66% obtained complete relief, and only 2% did not see any improvement. (Figure 5) This result is consistent with the findings of other authors.

According to the evaluation carried out using the Oswestry Test, a reduction was obtained, from 87.2% before surgery to a 12.1% in the first year after the procedure. (Figure 6)

On the Visual Analogue Scale, the pain was reduced from 81.9% in the presurgical evaluation, to 14.3 % the first year after the procedure. (Figure 7)

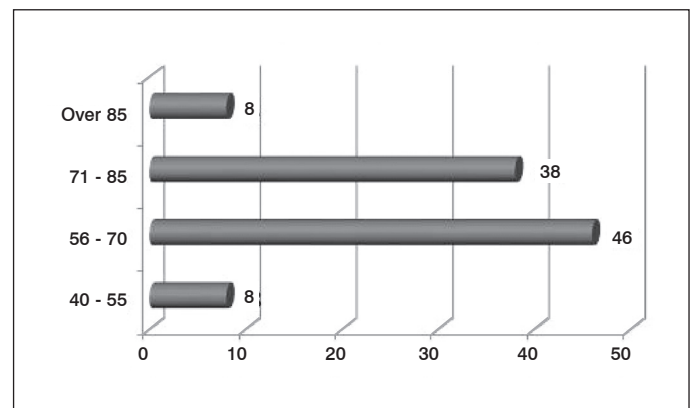


Figure 1. Distribution by age.

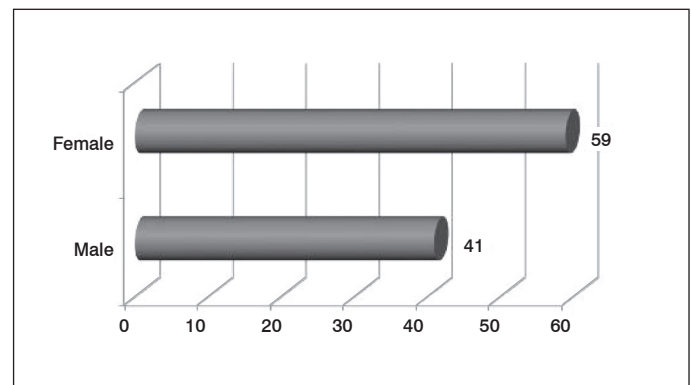


Figure 2. Distribution by sex.

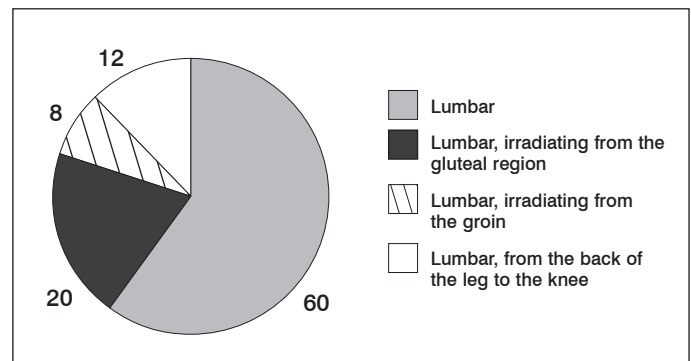


Figure 3. Location of the pain.

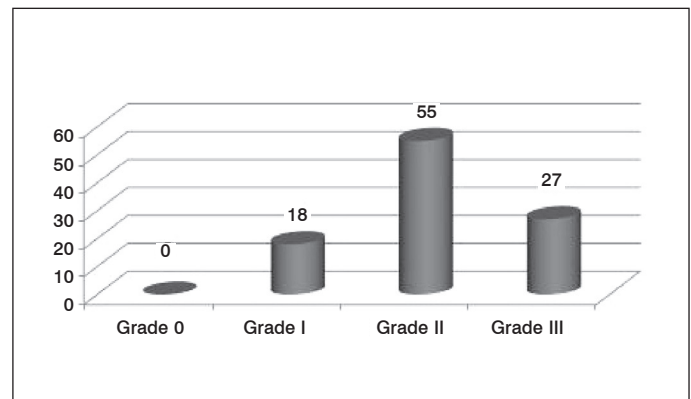


Figure 4. Patient distribution according to the classification of the facet joint degeneration by MRI.

Three levels were treated in 90% of the patients, and of these, the most frequent were L3-L4 L4-L5 L5-S1 with 53%. (Figure 8) The fusion of three levels is justified by the characteristic anatomical innervation of the facet joints.

The surgery time, after the learning curve was over in the first 50 interventions, was reduced to 15 minutes per level. (Figure 9) Bleeding was minimal (less than 10 cc) for each complete procedure. (Figure 10)

In relation to hospitalization time, 96% were discharged on the same day as the surgery, making it a completely outpatient procedure. (Figure 11)

We had 4 complications, which were: one misplacement which required open surgery to resolve it, without consequences; two superficial infections that responded to treatment with antibiotics; and one paravertebral bruise.

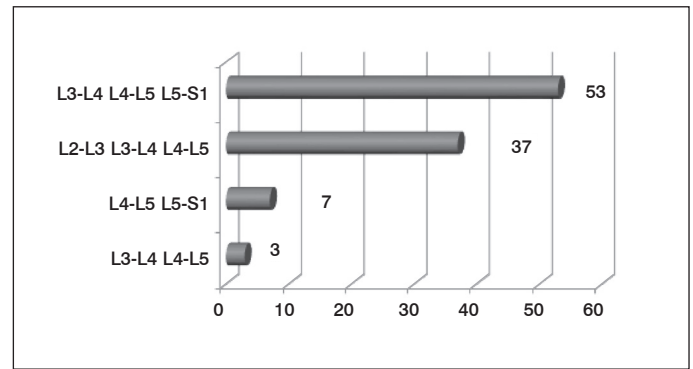


Figure 8. Levels treated.

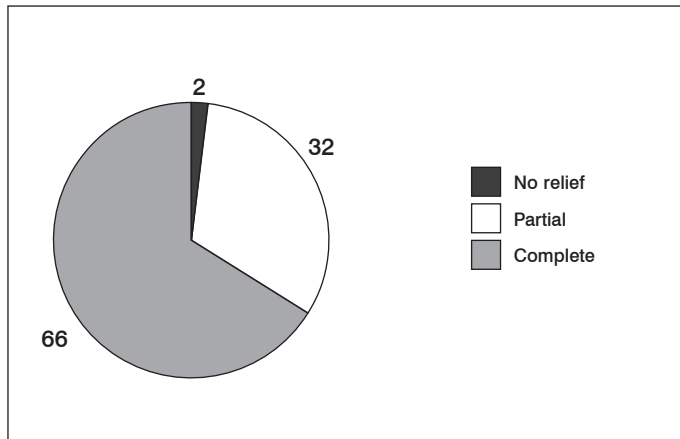


Figure 5. Patients' response to the facet blocks.

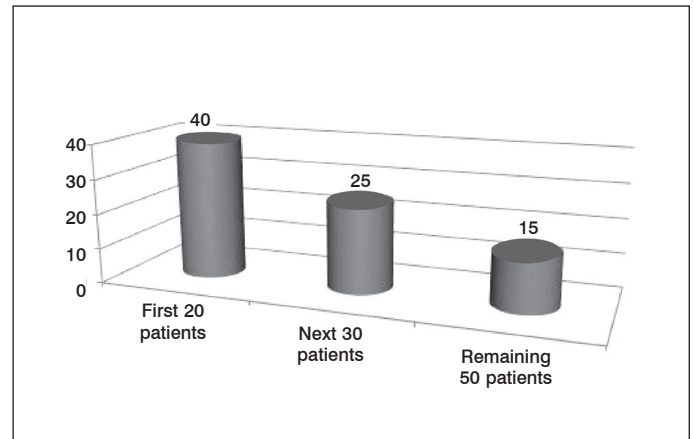


Figure 9. Surgery time.

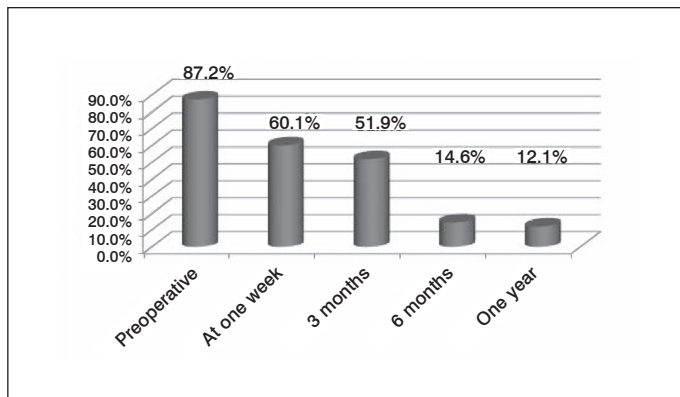


Figure 6. Oswestry Test.

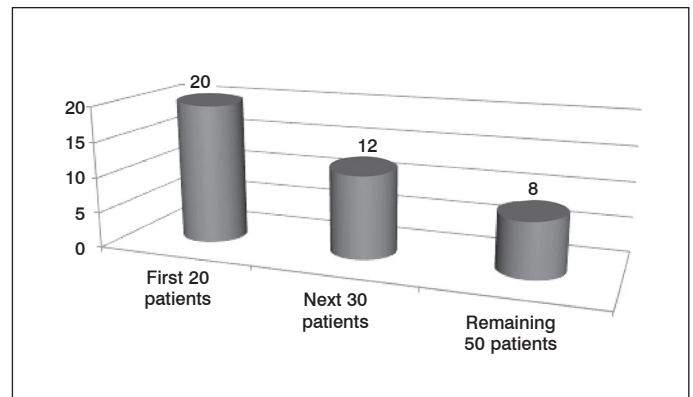


Figure 10. Bleeding.

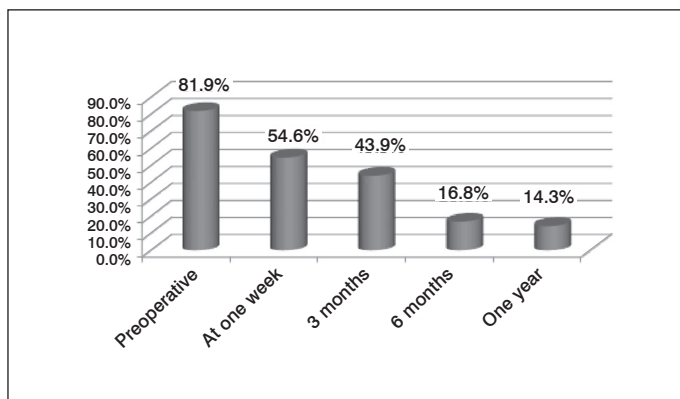


Figure 7. Visual Analogue Scale.

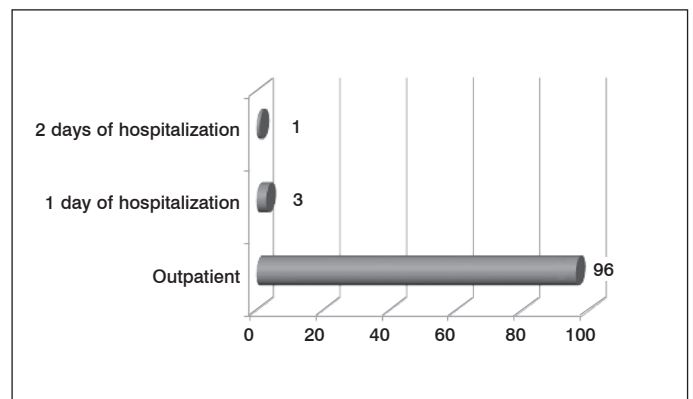


Figure 11. Hospitalization times.

CONCLUSIONS

Lumbar facet joint fusion via the percutaneous approach, with bone allograft, appears to be an effective treatment for lumbar facet joint disease, as well as being a safe procedure, with surgical time of less than an hour. It can be performed on an outpatient basis, with minimal bleeding and complications, and the return of patients to their daily activities is immediate.

With adequate and rigorous selection of patients and a carefully perfected technique, a significant reduction in VAS and Oswestry functional score was achieved, and maintained over time. However, despite our encouraging results, we believe that there is a need for a

greater number of cases and more follow-up time, in order to reach a definitive conclusion as to its effectiveness.

ACKNOWLEDGMENTS

To all my team and the staff of the International Neurosurgery Institute of the Larkin Hospital of Miami, Florida.

All authors declare no potential conflict of interest concerning this article.

REFERENCES

1. Dreyfuss PH, Dreyer SJ, Herring SA. Lumbar zygapophysial (facet) joint injections. *Spine (Phila Pa 1976)*. 1995;20(18):2040-7.
2. Goldthwait JE. The lumbo-sacral articulation: an explanation of many cases of lumbago, sciatica and paraplegia. *Boston Med Surg J*. 1911;164:365-72.
3. Ghormley RK. Low back pain with special reference to the articular facets, with presentation of an operative procedure. *JAMA*. 1933;101:773.
4. Schwarzer AC, Aprill CN, Derby R, Fortin J, Kine G, Bogduk N. Clinical features of patients with pain stemming from the lumbar zygapophysial joints. Is the lumbar facet syndrome a clinical entity? *Spine (Phila Pa 1976)*. 1994;19(10):1132-7.
5. Datta S, Lee M, Falco FJ, Bryce DA, Hayek SM. Systematic assessment of diagnostic accuracy and therapeutic utility of lumbar facet joint interventions. *Pain Physician*. 2009;12(2):437-60.
6. Gorbach C, Schmid MR, Elfering A, Hodler J, Boos N. Therapeutic efficacy of facet joint blocks. *AJR Am J Roentgenol*. 2006;186(5):1228-33.
7. Dreyer SJ, Dreyfuss PH. Low back pain and the zygapophysial (facet) joints. *Arch Phys Med Rehabil*. 1996;77(3):290-300.
8. Destouet JM, Gilula LA, Murphy WA, Monsees B. Lumbar facet joint injection: indication, technique, clinical correlation, and preliminary results. *Radiology*. 1982;145(2):321-5.
9. Boszczyk BM, Boszczyk AA, Korge A, Grillhösl A, Boos WD, Putz R, et al. Immunohistochemical analysis of the extracellular matrix in the posterior capsule of the zygapophysial joints in patients with degenerative L4-5 motion segment instability. *J Neurosurg*. 2003;99(Suppl 1):27-33.
10. Griffiths H, Parantainen H. Disease of the lumbosacral facet joints. *Neuroimaging Clin N Am*. 1993;3:567-75.
11. Manchikanti L, Singh V, Falco FJ, Cash KA, Pampati V. Evaluation of lumbar facet joint nerve blocks in managing chronic low back pain: a randomized, double-blind, controlled trial with a 2-year follow-up. *Int J Med Sci*. 2010;7(3):124-35.